

The Use of Hydroxyapatite Cement in Craniofacial Reconstruction: Experience in 130 Patients

F.D. BURSTEIN**, J.K. WILLIAMS**,
S. COHEN***, R. HUDGINS*,
W. BOYDSTON* and A. REISNER*

***The Center for Craniofacial Disorders, Children's Healthcare of Atlanta, Atlanta, GA, U.S.A.*

****Division of Plastic Surgery, Emory University, Atlanta, GA, U.S.A.*

****San Diego Children's Hospital San Diego, CA, U.S.A.*

We present our experience with the use of Hydroxyapatite Cement (HAC), in 130 patients over a seven-year period. This represents a continuation of our earlier reports on the use of Hydroxyapatite granules and cements, 1-4. There were 75 males, 55 females' ages 2.2 to 50 years, (mean 9.8 years). Follow up ranged from 6 months to seven years, (mean 26 mo). Eighty

patients underwent reconstruction for secondary orbit cranial defects after surgery for synostosis, 12 after surgery for hypertelorism, 22 for post-traumatic defects and sixteen for a variety of other defects. There were fifteen full thickness defects, of the skull measuring from 1cm in diameter to 7 cm in diameter reconstructed with a combination of titanium mesh, (10 patients), or resorbable mesh (5patients), and HAC, figs 1, 2. The amount of HAC paste used ranged from 8gm to 125 gm (mean 26 gm). Results were satisfactory and stable in all cases. There were 10 minor complications, (7.7%), ranging from a retained drain to postoperative seromas. Two patients had to have partial debridement after trauma resulted in fragmentation and chronic seromas. All were treated without loss of the contour correction. We believe that the success of our series can be attributed to several technical points: Avoidance of contact with paranasal sinuses, avoidance of oral exposure, incorporating antibiotics into the Hydroxyapatite powder, limiting the amount of material used, careful recipient site preparation and aggressive drainage and debridement of seromas.

Hydroxyapatite cement can be a useful adjunct in Craniofacial applications and is especially useful in correction of contour defects of the frontal bone and orbits. It has to date been stable and long lasting when used for cranioplasty in full thickness defects of the skull combined with a mesh superstructure.

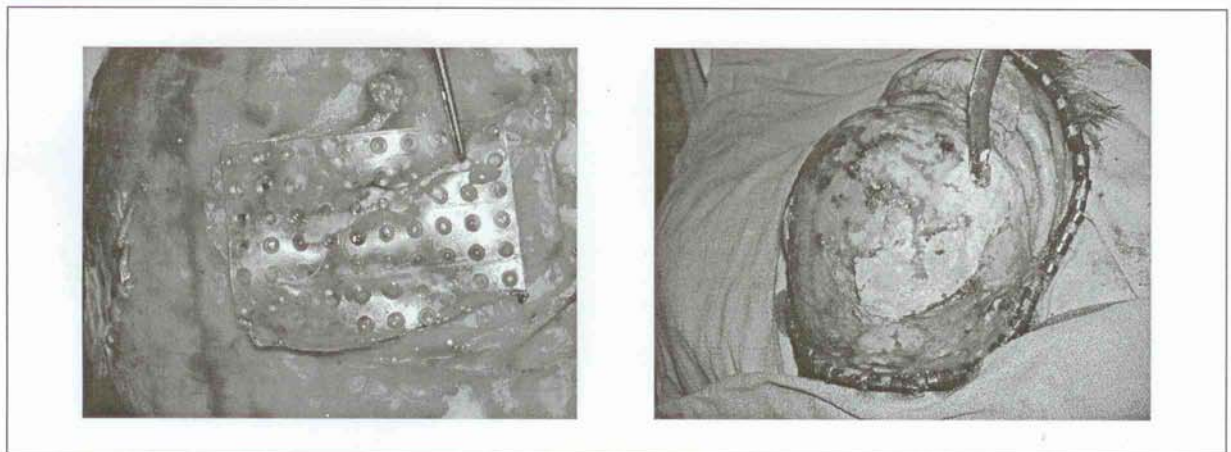


Fig 1: Intraoperative view of full thickness skull defect covered with resorbable mesh. Fig 2: Intraoperative view of full thickness skull defect in fig 1after mesh has been overlaid with Hydroxyapatite cement.

REFERENCES

1. Burstein FD, Cohen SR, Hudgins R, et al. The use of porous granular hydroxyapatite in secondary orbitocranial reconstruction. *Plast Reconstr Surg* 1997; 100:869-874
2. Burstein FD, Cohen SR, Hudgins R, et al. The use of Hydroxyapatite cement in secondary craniofacial reconstruction. *Plast Reconstr Surg* 1999; 104:1270-1275

