

Intralesional Laser Therapy Treatment for Hemangiomas: Technical Evolution

Fernando D. Burstein, MD, J. Kerwin Williams, MD, Ann R. Schwentker, MD, Farzad Nahai, MD

Atlanta, Georgia, USA

The authors have treated over 500 consecutive pediatric patients with voluminous hemangiomas (thickness of over 10 mm), since 1996. They were all treated with intralesional laser therapy using the potassium, titanyl, phosphate (KTP) laser. Since the initiation of KTP laser therapy for deep hemangiomas in 1996, the authors have significantly modified their treatment regimen. Changes from our original treatment protocol include lower power settings, and decreased treatment intervals. Additionally, we are now simultaneously treating the deep component, using intralesional KTP laser, and the superficial component using a pulsed dye laser. Fibrosis associated with intralesional therapy has been greatly decreased by injecting small amounts of dilute steroid solution during treatment of the deep component. While maintaining the efficacy of the procedure, we have been able to greatly decrease complications associated with it. The authors detail their current techniques as well as the evolution and rationale for modifying the original treatment regimen.

Key Words: Hemangioma, laser, intralesional

There is general agreement that hemangiomas that interfere with vital functions such as vision, eating, or respiration require prompt treatment.¹⁻³ Other generally accepted indications for treatment include ulceration, secondary infection, and substantial bleeding. Psychological distress may also be an acceptable indication for treatment. In 1993 Achauer reported his initial experience in the use of the KTP laser in 12 patients with voluminous hemangiomas.^{4,5} We became

interested in his work and started using similar techniques in 1996. We reported our initial experience with the use of the KTP and Nd: Yag laser for intralesional treatment in 2000.⁶ Our overall response rate of 90%, and overall results were encouraging. In our original series we encountered a similar rate of complications as those reported by other authors using comparable techniques.^{5,7,8} These included an ulceration rate of 20%, 2% skin burns, and transient facial nerve paresis in two patients with parotid hemangiomas. After reviewing our results, we began to modify our technique in order to minimize ulcerations, burns and damage to underlying soft tissues. In addition, we wished to better understand the dosimetry curve for intralesional laser therapy to optimize the results while decreasing the complication rate. Subsequently, we have treated an additional 400 patients and have been able to significantly decrease the rate of ulceration and other complications. We have also added standardized adjuvant measures, including treatment of the superficial capillary component, if there is one, with a pulsed dye laser and decreasing fibrosis by concurrent Kenalog injection during the period of treatment. Based on our experience over almost 10 years and 500 patients we present our current treatment protocol.

MATERIALS AND METHODS

Since our initial report in 1996, involving 100 patients, we have treated an additional 400 patients. All patients had lesions which were at least 10 mm in thickness (Figs 1-3). The KTP laser (513 μm) was used on all patients. The majority of patients had a superficial capillary component, in addition to the deep component, which was treated with the pulse dye laser, (585 μm). A 600- μ bare fiber was utilized to deliver the KTP laser energy directly into the lesion. All patients received a mask general anesthetic, usually without starting an intravenous line. No antibiotics were given unless necessary for SBE prophylaxis. Eyes were protected with metallic corneal shields or with tape and a moist sponge, depending on anatomic location. The fiber was

From the Center for Craniofacial Disorders, Children's Healthcare of Atlanta, Division of Plastic and Reconstructive Surgery Emory University, Atlanta Georgia.

Address correspondence and reprint requests to Fernando D. Burstein, MD, Suite 500, 975 Johnson Ferry Road, Atlanta, GA, 30342; E-mail: FBurstein@aol.com

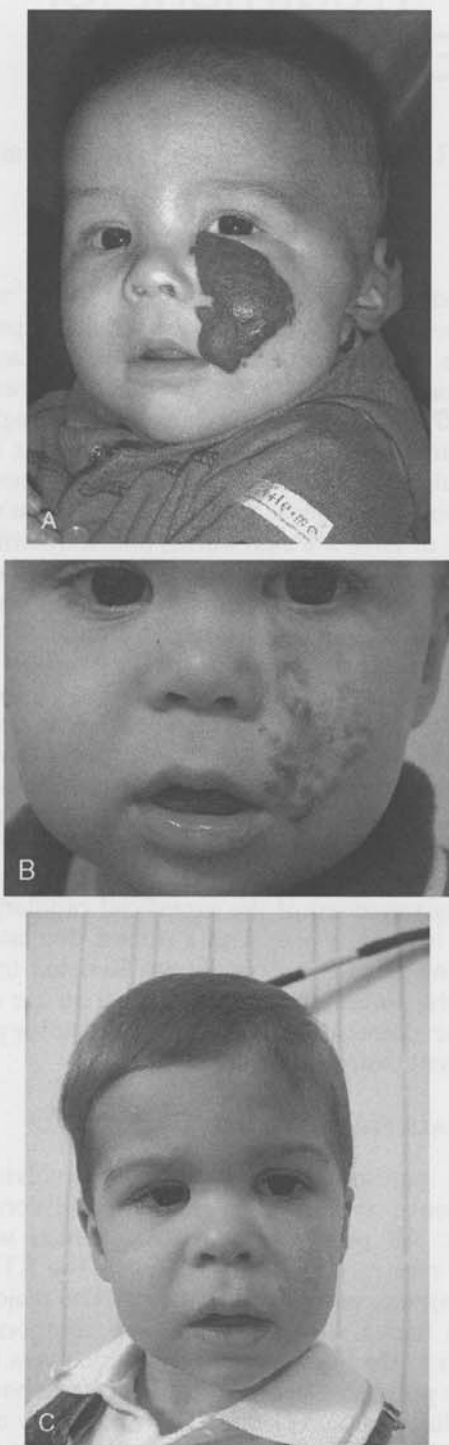

Fig 1 (A) A six-month-old infant with large facial hemangioma at the start of treatment. (B) Patient at end of intralesional KTP laser therapy; pulsed dye laser treatments continued. (C) Patient 12 months after end of pulsed dye laser treatments. Note slight skin atrophy and hyper pigmentation.

introduced, through an 18-gauge IV catheter inserted into unaffected skin 1–2 cm from the lesion. It was subsequently directed into the deep portion of the hemangioma. Great care was taken to stay at least 5 mm below the surface. Rapid radial passes were made throughout the lesion until there was palpable warming of the lesion, which served as the end point of treatment. The passes were made in multiple planes to include the entire volume of the lesion. Any superficial component was treated with a single pass of the pulsed dye laser at the same time. At the end of the procedure, the deep component was injected with 0.125% mepivacaine, 5% Kenalog solution. No more than 1.5 cc per lesion was injected. Power settings for the KTP laser ranged from 2 watts to a maximum of 5 watts. Power ranges for the tunable dye laser ranged from 6 joules up to a maximum of 15 joules. All lesions were coated with a topical antibiotic cream and the patients were discharged with no medications. Treatment intervals varied between four and six weeks. Four weeks was used in rapidly growing lesions impinging on the eyes, mouth or nose while six week intervals were applied to slowly growing lesions which did not have an immediate functional significance.

Approximately 0.05% of patients had systemic complications from the hemangiomas, including visceral hemangiomas or hemangiomas in the airway. These patients also received systemic steroids and/or Interferon, as per Hematology/Oncology recommendations. Results were graded from measurements of standardized pre-treatment photographs and at least three months after the last laser treatment as we have previously reported. Patients were followed for a minimum of six months after their last laser treatment (ranging from 6–36 months; mean 18 months).

RESULTS

All 400 patients had a response to the intralesional laser treatment, which sometimes did not become apparent for 4–6 weeks after treatment. Seventy percent of the patients had from 3–6 treatments, 20% had 6–9 treatments and 10% had > 9 treatments. All patients had at least a 75% reduction in the overall size of their lesion, including diameter and thickness. The remainder had at least a 50% reduction. Approximately 60% of these patients subsequently had outpatient surgical resection of residual skin atrophy and whatever bulk remained after 9–12 months, to allow for maximal therapeutic involution. No patients required intraoperative transfusion during the laser treatments or subsequent resection. There were no instances of nerve paresis or

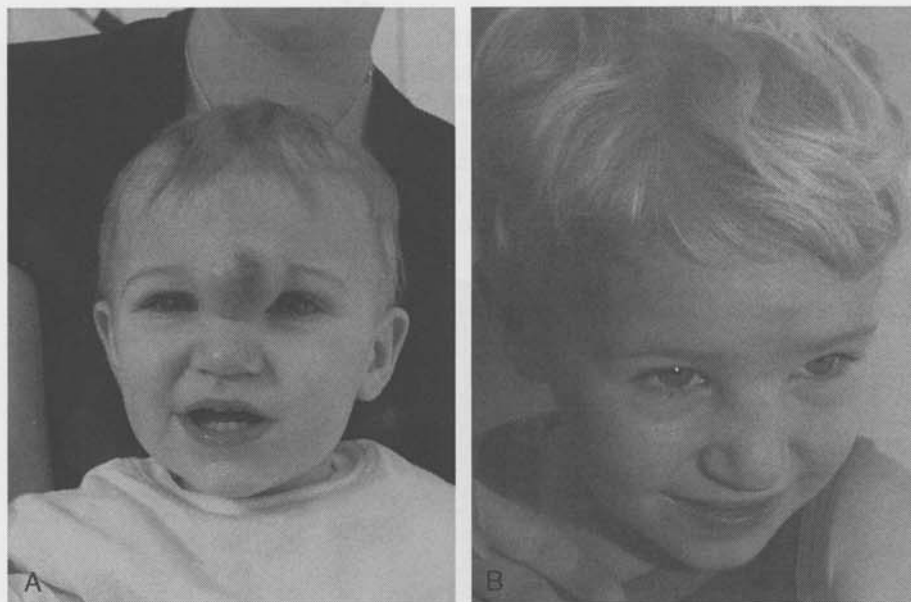

Fig 2 (A) A four-month-old infant with rapidly growing peri-orbital hemangioma at the start of treatment. (B) Patient 18 months after end of treatment with KTP and Pulsed Dye lasers. Atrophic skin and fibrosis have been excised.

paralysis. There was a 2% incidence of ulceration. There were no burns.

DISCUSSION

We found that the KTP laser is efficacious in the treatment of deep hemangiomas. This is consistent with reports from several authors and confirms our earlier experience.⁴⁻⁹ The most significant change from 1996 is that at that time we were using the KTP laser at 15–20 watts of power while today we have decreased the settings down to 2–5 watts. This has had multiple beneficial effects. The superficial ulceration rate, which was 20% in our original study, has dropped to approximately 2%. There have been no cases of facial nerve paralysis or paresis. There were two in the original series. There were no burns in the current series. The use of a lower power setting has allowed for a significantly decreased complication rate. It does mean that patients are now undergoing greater number of procedures. No patients in the current series received fewer than 3 treatments while 70% in our earlier series received only one treatment. In our current series, most patients required from 3–6 treatments for maximal efficacy. The exact mechanism and dosimetry curve of KTP laser treatment is not completely understood.⁷⁻⁹ We know that the 532- μ m wavelength energy is preferentially absorbed by red blood cells and that in addition there is a direct thermal effect, especially at high power. We speculate that our current lower power regimen relies more on the selective absorption, by the red blood cells within the

hemangioma, of the laser energy rather than on the thermal component. This explains the decreased rate of ulceration due to thermal necrosis. Adding simultaneous pulsed dye laser treatment of the superficial component also targets the specific absorption characteristics of the hemangioma. By decreasing the power of the KTP laser we can safely treat both the superficial and deep components simultaneously. Simultaneous treatment of the superficial and deep component decreases the overall number of treatments and the number of anesthetics required by the patient. We feel that increasing the number of treatments and decreasing the power setting allows the skin to heal between treatments, prevents undue thermal injury to the dermal/vascular plexus, and greatly reduces the chance of necrosis of the lesion.

In our earlier series, we injected the residual fibrous tissue which remained after treatment of voluminous hemangiomas with 10% Kenalog to decrease the amount of subcutaneous scar tissue that resulted with involution of the hemangioma. We have found that if we injected small increments of weak steroid solution at each treatment, mixed with mepivacaine, we not only eliminate postoperative pain, but also significantly reduce the amount of postoperative residual scar tissue. We do not feel that in the low volumes and high dilutions the Kenalog is being utilized, 5%, it significantly contributes to any type of therapeutic effect in terms of decreasing the growth of the hemangioma. We have not seen any subcutaneous fat atrophy in patients treated in this manner to date.

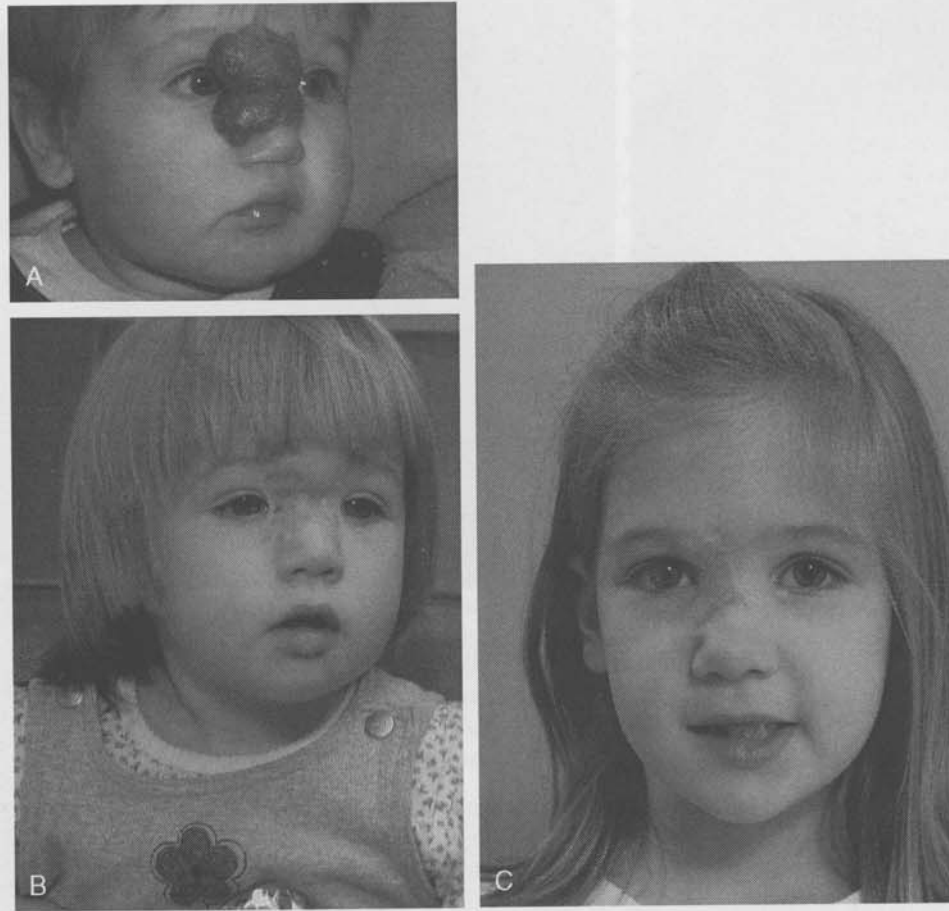


Fig 3 (A) A six-month-old infant with large periorbital hemangioma infringing on vision. (B) Patient at the end of intralesional KTP laser therapy; pulsed Dye laser treatments continued. (C) Patient two years after end of pulsed dye treatments and six months after initial excision of atrophic skin.

The overall rate of surgical excision of residual atrophic skin and residual hemangioma has not significantly changed from our initial report and the current series. It is our impression that the amount of skin that we are currently excising has markedly decreased. The main indication for surgical resection is atrophic skin, which occurs after a fairly large superficial external component. Certainly, the laser therapy can significantly shrink the amount of skin involved and prevent extensive scarring at the time of open surgery. We always warn that patients who have an initial significant skin component that open surgery may be required at the end of the laser treatments. We have not had to transfuse any patients who have undergone open surgery after their initial laser treatment. An additional benefit of the deep laser therapy is that the vascularity of the lesion is greatly decreased, making open surgery very simple. The current regimen has largely eliminated

texture changes caused by iatrogenic ulcerations thereby limiting the extent of the skin excision.

In our earlier report all patients were intubated and had intravenous lines, antibiotics and analgesics. Currently almost all patients get a mask anesthetic with no intravenous lines, no antibiotics and no post operative analgesics. This has been possible by the familiarity of the anesthesia staff with our regimen, the rapid speed of the procedure and infiltration with Mepivacaine. These changes have made intralesional laser therapy less expensive and less traumatic for the patients.

CONCLUSIONS

As with any new technique, we have had a learning curve with the utilization of the KTP laser for deep hemangiomas. We recommend introduction of the catheter through an IV catheter remote

to the lesion to prevent hot spots, KTP laser power settings between 2–5 watts, simultaneous treatment of the external component of the lesion with the pulsed dye laser, injection of diluted steroid with Mepivacaine at each treatment and a treatment interval of 4–6 weeks. These methods have allowed us to safely treat over 400 patients with very few complications and good results.

REFERENCES

1. Wisnicki JL. Hemangiomas and vascular malformations. *Ann Plast Surg* 1984;1–6
2. Jacobs AH. Strawberry hemangiomas: the natural history of untreated lesions. *Calif Med* 1957;86:8–10
3. Williams BH. Facial Bone changes with vascular tumors in children. *Plast Reconstr Surg* 1979;63:309–316
4. Achauer BM, Vanderkam VM, Padilla JF. Clinical experience with the tunable dye laser (585 nm) in treatment of capillary vascular malformations. *Plast Reconstr Surg* 1993;1233–1241
5. Achauer BM. Intralesional bare fiber treatment of hemangioma of infancy. *Plast Reconstr Surg* 1998;101:1212–1217
6. Burstein FD, Simms C, Cohen S, et al. Intralesional laser therapy of extensive hemangiomas in 100 consecutive patients. *Ann Plast Surg* 2000;44:188–194
7. Clymer MA, Fortune SD, Reinisch L, et al. Interstitial Nd: YAG photocoagulation for vascular malformations and hemangiomas in childhood. *Arch Otolaryngol Head Neck Surg* 1998;431–436
8. Achauer BM, Chang C, VanderKam VM, et al. Intralesional photocoagulation of periorbital hemangiomas. *Plast Reconstr Surg* 1999;103:11–16
9. Berlien HP, Waldschmidt J, Muller G. Laser treatment of cutaneous and deep vessel anomalies. In: Waidelich W, Waidelich R, eds. *Laser optoelectrics in medicine*. Berlin: Springer Verlag, 1998:526–528