

## STATE OF THE ART

**EDITOR'S NOTE:** This is the eighth in a series of state-of-the-art papers covering all aspects of craniofacial care. To be published throughout volumes 36 and 37 of the CPCJ, these papers will reflect on where we have been, where we are now, and the challenges we face in the new millennium.

### Bone Substitutes

FERNANDO D. BURSTEIN, M.D., F.A.A.P., F.A.C.S.

**The search for the ideal bone substitute began hundreds of years ago, and continues today. While numerous choices have been proposed and tested, with varying degrees of success, there remain many challenges related to the use of bone substitutes in craniofacial reconstruction. This paper presents a review of the history of bone substitute research, a discussion of currently popular materials, and elucidation of the challenges to be faced as we approach the new millennium.**

**KEY WORDS:** *allograft, autogenous bone, bone substitutes, craniofacial reconstruction, hydroxyapatite cement*

The search for the ideal bone substitute has spanned hundreds of years and continues today. The gold standard against which all organic and nonorganic substitutes are measured is autogenous bone (Albrektsson, 1980; Freidlander, 1987). Autogenous bone has ideal structural and biologic properties. These include the ability to be revascularized by both inosculation and creeping substitution as well as the ability to regenerate and produce a mixture of cancellous and cortical bone and, in certain circumstances, grow with the patient. Before the advent of modern immunology, certain biologic bone substitutes such as ivory and animal bone were utilized with little success. Later, inorganic compounds such as plaster of paris enjoyed a period of popularity (Edberg, 1930; Tarsoly, 1963; Frame, 1980). Although historically interesting, these early attempts often led to rejection, absorption, and infection.

In modern craniofacial surgery, several organic and inorganic bone substitutes have gained popularity. Recently, a combination of a biologically inert carrier coupled with an osteogenic-inducing protein has been studied (Urist et al., 1984; Damien and Parsons, 1991; Costantino et al., 1993; Cook et al., 1995). Regardless of the type of bone substitute utilized, certain requirements are necessary to provide the best chance for success. These include a viable vascularized recipient bed, contact with either viable bone, from which osteoblastic cells can migrate into the implant and form a biologic interface, or periosteum, which can provide osteoblastic cells

for ingrowth into the implant (Burstein and Canalis, 1985; Goldberg and Stevenson, 1987). The dura, particularly in young individuals, can also be a valuable source of osteoblastic precursor cells that can populate the bone substitute material (Glowacki et al., 1981). In addition to these requirements, adequate soft-tissue coverage to prevent bacterial contamination and subsequent infection is essential regardless of the bone substitute chosen.

There are several types of bone substitutes that have applicability in craniofacial surgery. Cadaveric allografts have had limited application in craniofacial surgery, mostly in the reconstruction of large cranial vault defects. Their variable rates of resorption due to incomplete vascularization and unpredictable creeping substitution have limited their utilization (material (Glowacki et al., 1981; Montgomery et al., 1990; Morales et al., 1993). Although initially the cortical allografts may have some load-bearing capability, long-term structural stability may be jeopardized by osteoclastic resorption (Morales et al., 1993). In recent years, the possibility of viral transmission in allograft products has in many cases decreased their popularity. We do not recommend allograft use in areas that will be exposed to sinus contents or subjected to oral contamination since these grafts may be a nidus for bacterial infection.

A number of promising synthetic bone substitutes are currently in use clinically. Calcium sulfate, also known as plaster of paris, was initially used in the late 1800s to fill bone cavities in patients with tuberculous cavities (Tarsoly, 1963; Frame, 1980). Its advantage is that it can be used as a putty that is easily malleable into any shape and can easily fill even irregular defects. Although utilized during the Vietnam conflict as a space filler in craniofacial defects, it has largely lost popularity because of its unpredictable degradation and resorption characteristics.

Dr. Burstein is Associate Clinical Professor, Division of Plastic and Reconstructive Surgery, Emory University School of Medicine, and Director, Scottish Rite Center for Craniofacial Disorders, Atlanta, Georgia.

Submitted December 1998; Accepted August 1999.

Reprint requests: Dr. Fernando Burstein, Scottish Rite Children's Medical Center, 1001 Johnson Ferry Road, Atlanta, GA 30342.

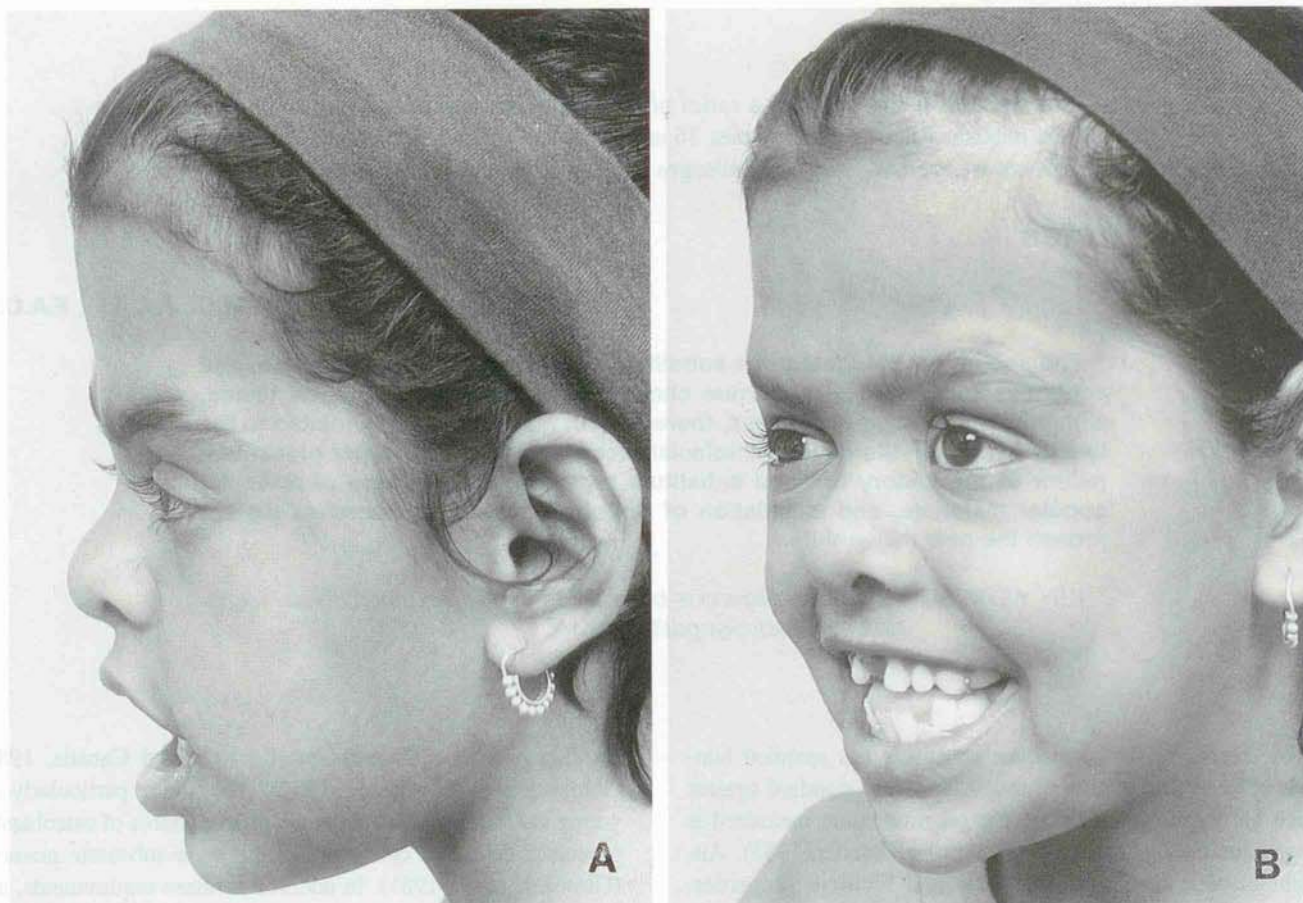

FIGURE 1 Lateral (A) and oblique (B) views of patient with Apert Syndrome 2 years after facial bipartition with monoblock advancement. Note supraorbital bony resorption with ridging of brow and temporal hollowing.

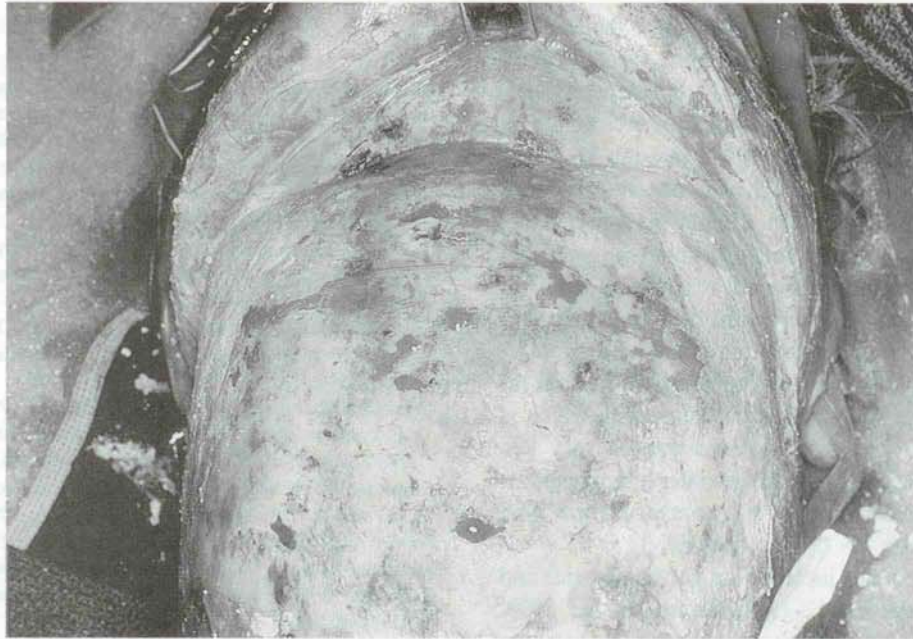
Bioglasses are silicophosphatic chains with chemical activity that can exchange ionic and molecular groups with an osseous recipient site. Because of this property, they have shown promise in their capacity to osseointegrate with bone. Currently, the Food and Drug Agency has approved their limited use for dentoalveolar applications (Nery and Lynch, 1978; Ducheyne, 1994).

Several different forms of calcium phosphates are currently in use for bone repair in the craniofacial skeleton. Tricalcium phosphates (TCP) are biodegradable; however, their biodegradation profile is somewhat irregular (Winter et al., 1981; Klein et al., 1986). Experimental studies have also shown that, while the TCP may biodegrade, it may not be accompanied by new bone formation in the resultant defect (Klein et al., 1986). TCP may have applications in craniotomy repair when prepared in its porous channeled form that allows for bone ingrowth through osteoconduction (Glowacki et al., 1981; Bucholz et al., 1987).

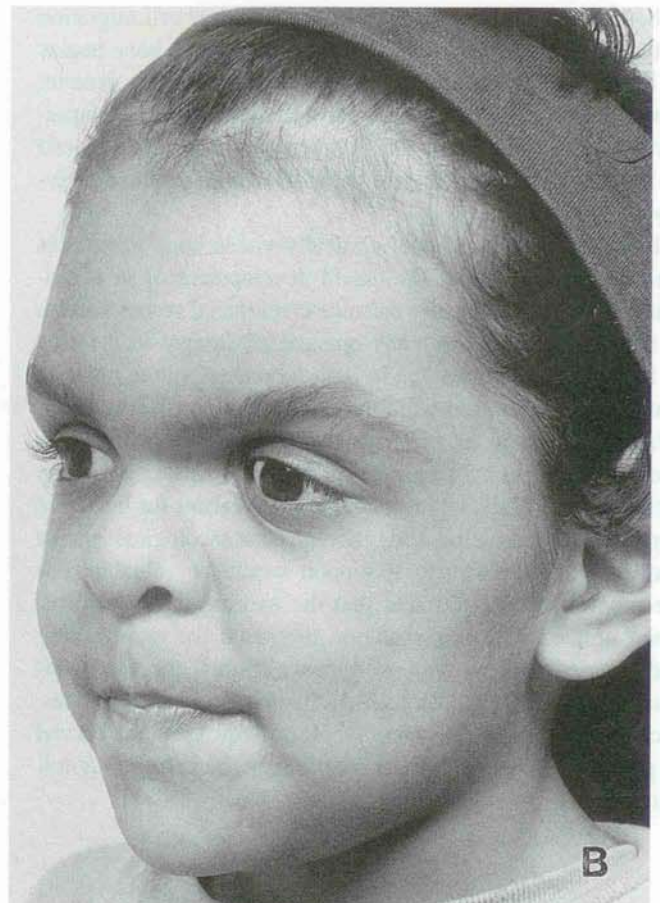
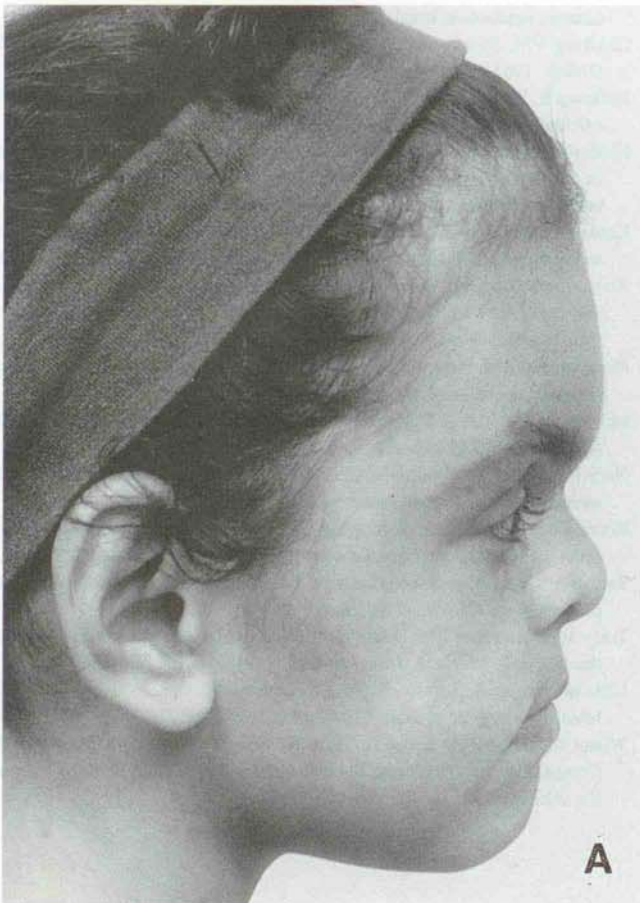
Hydroxyapatite is available in both ceramic and nonceramic forms. Ceramic hydroxyapatite has been most widely used in clinical applications. Hydroxyapatite can be laboratory derived or prepared from naturally occurring corals. The advantages of hydroxyapatite are that it is porous, chemically stable, and nonbiodegradable (Tracy and Doremas, 1984; Bucholz et al.,

1987). It allows for good bony ingrowth and incorporation into defects (Tracy and Doremas, 1984). It has very limited stress-bearing capacity, although it has been successfully used to fill gaps in craniofacial osteotomies (Rosen, 1989). An injectable hydroxyapatite is also available. We have previously used the granular hydroxyapatite mixed with blood and thrombin to fill in secondary orbitocranial defects with excellent success (Burstein et al., 1997). The clinical drawbacks of granular hydroxyapatite have been the 3–5-day setting period before permanent form is achieved; during the setting period, the granular hydroxyapatite can migrate to the lowest point in the defect, causing unsightly bulging. Furthermore, the best results were obtained when an intact pericranial envelope was used to cover the material, preventing particle migration. Volume retention was noted to be excellent when adequate periosteal coverage of the implant was obtained.

A new product consists of tetracalcium phosphate and dicalcium phosphate dihydrate. This is mixed with sterile water and, during an isothermic reaction, converted to microporous hydroxyapatite (Costantino et al., 1991). The curing period is approximately 20 minutes when mixed with water. We have been utilizing it mixed with monosodium phosphate, which decreases the curing time to less than 10 minutes. This material, once mixed, becomes a fairly dense paste that can be quite



**FIGURE 2** Patient in Figure 1 undergoing skull reconstruction with hydroxyapatite paste. Material has been added to the frontal bone defects and to the temporal hollows.



**FIGURE 3** Lateral (A) and oblique (B) views of patient in Figure 1 one year after procedure depicted in Figure 2. Note rounding of forehead contour and filling of temporal hollowing.

easily applied, particularly over the orbitocranial region (Ishikawa et al., 1925). Once dry in the operating theater, it will not shift and, although an intact pericranial envelope is desirable, we have had no difficulty when local pericranium was not available to cover the material (Figs. 1 through 3). In addition, there is no edge effect, which was occasionally seen with block hydroxyapatite and even granular hydroxyapatite. We have been successful in combining this material with thin titanium mesh, which provides torsional strength, in repair of full-thickness skull defects. We currently use the hydroxyapatite paste mixed with monosodium phosphate and approximately 250 mg of a first-generation cephalosporin. Initial indications are that the paste binds the cephalosporin, which is then released within the wound. We have noted a very low extrusion infection rate with either the granular hydroxyapatite or the hydroxyapatite paste. In over 60 patients, our infection or extrusion rate is under 3% (Figs. 1 through 3).

A new class of compounds includes the polylactic acids and polyglycolic acids (Urist et al., 1984; Kenley et al., 1993, 1994). These are currently being investigated as carrying agents for proteins that have osteo-inductive capabilities. Most notably is the bone morphogenic protein (BMP) and its various derivatives, which have been coupled with polylactic acid carriers. The strategy with this bone substitute is to have the carrier fill the void in the bone defect, allowing time for the BMP to be delivered to the site and induce osteogenic cell migration to the site. The polymer would then biodegrade as bone begins to fill the defect induced by the bone morphogenic protein. Several problems remain to be solved, including rather unpredictable resorption rates, the inflammatory response induced by the resorbable carriers, and variability in the payload delivery.

In summary, a number of clinically viable bone substitutes are currently available. Continued development of new biomaterials will undoubtedly enhance craniofacial reconstruction in the future. There are many ongoing challenges in the area of bone substitute research. To date, a bone substitute material that will allow teeth to erupt through it while providing structural rigidity eludes us. Materials that will allow bony ingrowth and provide torsional strength will be useful in surgery of the facial skeleton. Development of a reliable carrier for bioactive bone-inducing proteins and various pharmacological agents that also provides structural support would be valuable. For the moment, we have found that the hydroxyapatite cement, when utilized with monosodium phosphate for rapid curing and coupled with antibiotics, appears optimal for non-load-bearing orbitocranial reconstruction. For load-bearing areas, such as after LeFort I osteotomy, block hydroxyapatite carved to precisely fit into the defect may be an alternative to autologous bone.

## REFERENCES

- Albrektsson T. *In vivo* studies of bone grafts. *Orthop Scand*. 1980;51:9–17.
- Bucholz RW, Carlton A, Holmes RE. Hydroxyapatite and tricalcium phosphate bone graft substitutes. *Orthop Clin North Am*. 1987;18:323–334.
- Burstein FD, Canalis RF. Studies on the osteogenic potential of vascularized periosteum: behavior of periosteal flaps transferred onto soft tissue. *Otolaryngol Head Neck Surg*. 1985;93:731–735.
- Burstein S, Cohen S, Hudgins R, Boydston W. The use of porous granular hydroxyapatite in secondary orbitocranial reconstruction. *Plast Reconstr Surg*. 1997;100:869–874.
- Cook SD, Wolfe MW, Salked SL, et al. Recombinant human osteogenic protein-1 (rh OP-1) heals segmental defects in nonhuman primates. *J Bone Joint Surg*. 1995;77A: 734–755.
- Costantino PD, Friedman CD, Jones K, Chow LC, Pelzer HJ, Sisson GA. Hydroxyapatite cement I: basic chemistry and histological properties. *Arch Otolaryngol Head Neck Surg*. 1991;117:379–384.
- Costantino PD, Friedman CD, Lane A. Synthetic biomaterials in facial plastic and reconstructive surgery. *Facial Plast Surg*. 1993;9:1–15.
- Damien CJ, Parsons JR. Bone graft and bone graft substitutes: a review of current technology and applications. *J Appl Biomater*. 1991;2:187–208.
- Ducheyne P. Bioactive ceramics. *J Bone Joint Surg Br*. 1994;76:861–862. Editorial.
- Edberg E. Some experiences in filling osseous cavities with plaster. *Acta Chir Scand*. 1930;67:313–319.
- Frame JW. A composite of porous calcium sulphate dihydrate and cyanoacrylate as a substitute for autogenous bone. *J Oral Surg*. 1980;38:251–256.
- Freidlander GE. Current concepts review: bone grafts. *J Bone Joint Surg*. 1987; 69A:–786.
- Glowacki J, Altobelli D, Mulliken JB. Fate of mineralized and demineralized osseous implants in cranial defects. *Calcif Tissue Int*. 1981;33:71–76.
- Goldberg VM, Stevenson S. Natural history of autografts and allografts. *Clin Orthop*. 1987;225:7–16.
- Ishikawa K, Takagi S, Chow L, et al. Properties and mechanisms of fast-setting calcium phosphate cements. *J Mater Sci Mater Med*. 1925;6:528–533.
- Kenley R, Marden L, Turek T, Jin L, Ron E, Hollinger JO. Osseous regeneration in the rat calvarium using novel delivery systems for recombinant human bone morphogenic protein-2. *J Biomed Mater Res*. 1994;28:1130–1147.
- Kenley R, Yim K, Abrams J, Ron E, Turek T, Marden LJ, Hollinger JO. Biotechnology and bone graft substitutes. *Pharmacol Res*. 1993;10:1393–1401.
- Klein C, de Groot K, Driesen A, vander Lubbe HB. A comparative study of different [beta]-whitlockite ceramics in rabbit cortical bone with regard to their biodegradation behavior. *Biomaterials* 1986;7:144–146.
- Montgomery DM, Aronson DP, Lee CL, LaMont RL. Posterior spinal fusion: allograft versus autograft bone. *J Spinal Disord*. 1990;3:370–375.
- Morales DO, Peltine KA, Salib RM. A biomechanical study of bone allografts. *Orthop Trans*. 1993;17:–12.
- Nery EB, Lynch KL. Preliminary clinical studies of bioceramics in periodontal osseous defects. *J Periodontol*. 1978;49:523–527.
- Rosen HM. Porous black hydroxyapatite as an interposition graft substitute in orthognathic surgery. *Plast Reconstr Surg*. 1989;985–990.
- Tarsoly E. The filling of bone cavities with a mixture of egg shell and plaster of paris. *Acta Chir Acad Sci Hung*. 1963;4:63–72.
- Tracy BM, Doremas RH. Direct electron microscopy studies of the bone-hydroxyapatite interface. *J Biomed Mater Res*. 1984;18:719–726.
- Urist MR, Leitz A, Lawson E. Beta tricalcium phosphate delivery system for bone morphogenic protein. *Clin Orthop*. 1984;187:277–280.
- Winter M, Griss P, de Groot K, Tagai H, Heimke G, von Dijk HJ, Sawai K. Comparative histocompatibility testing of seven calcium phosphate ceramics. *Biomaterials*. 1981;2:159–160.