

# The Use of Porous Granular Hydroxyapatite in Secondary Orbitocranial Reconstruction

Fernando D. Burstein, M.D., Steven R. Cohen, M.D., Roger Hudgins, M.D.,  
and William Boydston, M.D., Ph.D.

Atlanta, Ga.

The search for the ideal bone-graft substitute has been the focus of many research and clinical studies. Hydroxyapatite is one such material that combines osseointegration with maintenance of implant volume and excellent durability. We present our experience in 29 patients ranging in age from 3 to 22 years (mean age 10.5 years) who underwent secondary orbitocranial reconstruction of large contour defects utilizing porous granular hydroxyapatite. Follow-up ranges from 6 to 72 months (mean 30 months). Indications for secondary surgery included residual bony contour defects of the frontal bone, temporal areas, and superior orbital rims that were present 12 months or more after initial surgery. There was one infection secondary to a chronic seroma necessitating removal of the porous hydroxyapatite, and one patient required revision for underfilling and another for overfilling. Excellent permanent contour improvement was obtained with a smooth skin surface in the remainder of our patients. The contour corrections have been long lasting, without evidence of porous hydroxyapatite resorption or migration. (*Plast. Reconstr. Surg.* 100: 869, 1997.)

There has been interest in biomaterials that can be used as bone substitutes in craniofacial and maxillofacial surgical applications.<sup>1,2</sup> Certain mechanical and biologic properties are desirable but difficult to obtain; these include biointegratability, mechanical strength, torque resistance, ease of application, and stability over time.<sup>1-3</sup> Hydroxyapatite is a synthetic bone-graft substitute made by conversion of the calcium carbonate exoskeleton of sea coral that is available in block and granular forms. Its porous structure behaves as a scaffold and allows ingrowth of native surrounding osseous tissues, with bony union seen as early as 90 days after implantation.<sup>3,4</sup> The use of block hydroxyapatite to span osteotomy gaps in maxillofacial surgery has been successful despite its fragility

when submitted to rotatory stresses.<sup>5-7</sup> Block hydroxyapatite is difficult to shape and fix because of its inherent fragility, particularly after it absorbs moisture, making it less than ideal for filling of contour defects.<sup>6-9</sup> The edges of the blocks often show below relatively thin soft-tissue covering such as the forehead and peri-orbital regions. Porous granular hydroxyapatite, although lacking in compressive strength, is ideal for filling contour defects in the upper facial skeleton. Porous granular hydroxyapatite is well tolerated by both soft and osseous tissues, can be mixed into an easily applicable paste, and does not show under relatively thin soft-tissue cover. Marchac<sup>10</sup> in 1991 and Byrd et al.<sup>11</sup> in 1993 reported their experience utilizing hydroxyapatite granules for a variety of small craniofacial skeletal defects in various anatomic locations. Although the use of block hydroxyapatite in maxillofacial applications and of porous hydroxyapatite in limited orbitocranial defects has been largely successful, little is known regarding the use of porous hydroxyapatite for large contour defects of the orbitocranial region.<sup>5,7-11</sup> Furthermore, the use of porous hydroxyapatite in growing children and adolescents has not been specifically addressed. We report on our use of porous hydroxyapatite for reconstruction of clinically significant orbitocranial contour defects in infants, adolescents, and young adults.

## PATIENTS AND METHODS

Twenty-nine patients ranging in age from 3 to 22 years (mean, 10.5 years; 16 males and 13 females) underwent porous hydroxyapatite re-

construction of a variety of frontal bone, temporal, and upper orbital bony contour defects. These included 9 patients with frontal-basilar trauma and 17 patients who had surgery for craniosynostosis (Table I). All patients were at least 1 year after initial reconstruction at the time of their secondary surgery. Follow-up was from 6 to 72 months (mean 30 months). Porous hydroxyapatite (granule size 425 to 1000  $\mu\text{m}$ ) was mixed in a ratio of 1 cc porous hydroxyapatite to  $\frac{1}{2}$  cc of the patient's blood and  $\frac{1}{2}$  cc of microfibrillar collagen to form a dense paste of adherent porous hydroxyapatite. The bony defects were all approached through a coronal incision, taking great care to stay in a supraperiosteal plane. The periosteum was raised as an anteriorly based vascularized flap (Figs. 1 and 2). In patients in whom the temporal areas needed to be addressed, the temporalis muscle was raised in the deep subperiosteal plane. Protuberant hardware was removed, and all bony peaks were burred down before filling the defects with the porous hydroxyapatite paste. The periosteal flaps were

TABLE I  
Patient Summary

Age (years), Sex	Diagnosis	Complications
11, M	Left coronal synostosis	None
22, M	Fibrosis dysplasia	Excess porous hydroxyapatite
2, F	Metopic synostosis	None
5, M	Sagittal synostosis	None
18, M	Trauma	None
13, M	Crouzons disease	None
23, F	Trauma	None
13, F	Right coronal synostosis	None
11, F	Trauma	None
18, M	Left coronal synostosis	Deficient porous hydroxyapatite
10, M	Sagittal synostosis	None
14, M	Trauma	None
13, F	Facial clefting	None
4, F	Metopic synostosis	None
22, F	Trauma	None
15, M	Trauma	None
4, F	Bicoronal synostosis	None
18, F	Trauma	None
4, M	Metopic synostosis	None
18, M	Trauma	None
8, M	Trauma	None
5, F	Metopic synostosis	None
5, F	Facial clefting	Infection of porous hydroxyapatite
3, M	Metopic synostosis	None
7, M	Aperts	None
5, F	Metopic synostosis	None
3, M	Metopic synostosis	None
2, M	Sagittal synostosis	None
10, F	Bicoronal synostosis	None

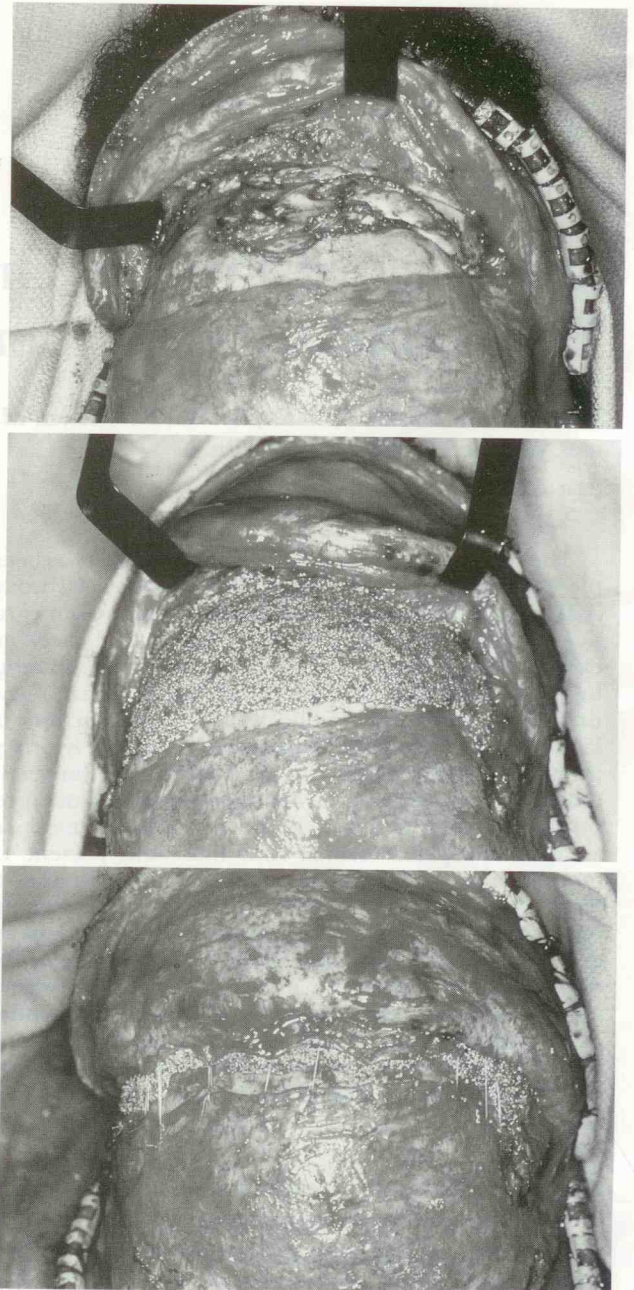


FIG. 1. (Above) Intraoperative photograph of patient 1 year after open reduction and internal fixation for fronto-basilar trauma. Bicoronal scalp flap is at top of photograph. Note irregular bone resorption along fronto-orbital complex. Periosteal flap is under black retractors. (Center) Intraoperative photograph. After burring down high points, all contour defects are filled with porous hydroxyapatite paste. Note feathering of porous hydroxyapatite thickness at edges. (Below) Periosteal flap has been sutured to the intact posterior periosteal edge, covering and retaining the porous hydroxyapatite construct. Bicoronal flap is at top of photograph.

then sutured at the borders of the bony defects in order to create a sealed pocket for the porous hydroxyapatite paste. A neurosurgical type head dressing was kept on for 5 days post-

