

# Surgical Therapy for Severe Refractory Sleep Apnea in Infants and Children: Application of the Airway Zone Concept

Fernando D. Burstein, M.D., Steven R. Cohen, M.D., Peter H. Scott, M.D., Gerald R. Teague, M.D., Gary L. Montgomery, M.D., and Allison V. Kattos, R.N.

Atlanta, Ga.

Obstructive sleep apnea in children may result in hypoxia, right-sided heart failure, and sudden death. Children with craniofacial deformities and/or cerebral palsy are at high risk for the development of obstructive sleep apnea. Prompted by the excellent results obtained in adults when sleep apnea was managed by an aggressive surgical approach, we undertook a similar treatment philosophy in children. Twenty-eight patients representing four diagnostic groups were evaluated and operated on for severe upper airway obstruction: Down syndrome ( $n = 5$ ), cerebral palsy ( $n = 12$ ), Goldenhar syndrome ( $n = 4$ ), and a mixed apnea group ( $n = 7$ ). Tracheostomy was avoided in 25 of 28 patients (89 percent), with a marked decrease in apnea (median 90 percent) and hypopnea (median 87 percent) episodes. Tongue hyoid suspension and skeletal expansion procedures, which were the mainstay of treatment, were applied for the first time in children and adolescents with obstructive sleep apnea. (*Plast. Reconstr. Surg.* 96: 34, 1995.)

Sleep apnea in children may result in severe sequelae. These may range from poor school performance, to daytime somnolence, to right-sided heart failure and death.<sup>1-3</sup> These problems are magnified in the neurologically impaired child and in children with craniofacial anomalies.<sup>4-6</sup> Sleep apnea can have both a central and a peripheral obstructive component in variable proportions.<sup>1-3</sup> Central apnea may be due to a variety of problems, such as brainstem anomalies or compression, increased intracranial pressure, or immaturity of the central nervous system.<sup>1-3</sup> The peripheral obstructive component is always due to one or more physical obstructions situated between the nares and bronchi.<sup>7,8</sup>

Accepted treatments for obstructive sleep apnea include medical modalities such as positive-pressure mask ventilation, supplemental oxygen, temporary nasopharyngeal airways, and oropharyngeal airway placement.<sup>1-3</sup> Standard surgical approaches include tonsillectomy, adenoidectomy, uvulopalatopharyngoplasty, and relief of nasal septal obstruction.<sup>8,9</sup> Unfortunately, severely affected children may be refractory to standard medical and surgical treatments. These children may have no alternative other than permanent tracheostomy. While effective, this entails a significant increase in the level of home or institutional care required for the child. There also may be deleterious psychological, communicative, and social effects in the affected child and his or her family due to permanent tracheostomy.<sup>10-12</sup>

The focus of the present investigation is to provide a logical, sequential treatment strategy for children with severe obstructive sleep apnea refractory to standard medical and surgical treatments. Our goal is to avoid permanent tracheostomy whenever possible. In order to better define the anatomic problems, we have developed the concept of functional and anatomic airway zones (Fig. 1). Zone I extends from the nares to the velum. Zone II extends from the lips to the hypopharynx, excluding all laryngeal structures. Zone III extends from the epiglottis to the trachea, including the larynx. Finally, zone IV extends from the subglottis to the bronchi. We report on the application of the airway zone concept and multidisciplinary

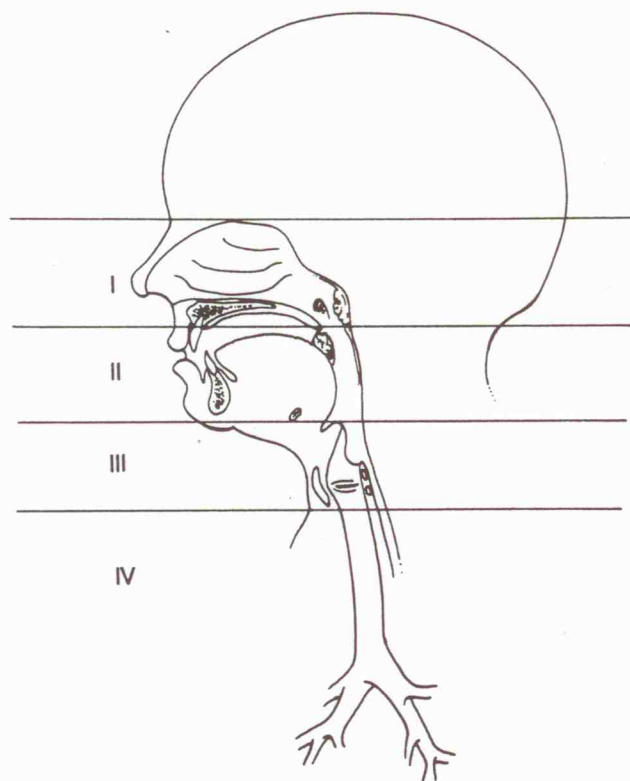


FIG. 1. Functional and anatomic airway zones: I, nares to velum; II, lips to hypopharynx; III, epiglottis to trachea; and IV, subglottis to bronchi.

team approach in the management of complex obstructive sleep apnea in children.

#### PATIENTS AND METHODS

Twenty-eight patients ranging in age from 18 months to 17 years (mean 5 years and 3 months) were treated surgically for severe refractory sleep apnea. All had anatomic sites of obstruction in zones I and II. There were 17 males and 11 females. Follow-up ranged from 6 to 48 months (mean 16 months.) All our patients had multiple problems ranging from cerebral palsy to Down syndrome. For purposes of discussion, patients are divided into four diagnostic groups: group I (mixed), group II (Down syndrome), group III (cerebral palsy), and group IV (Goldenhar syndrome) (Table I). All prospective surgical candidates were evaluated by the pediatric pulmonology service (Scott, Teague, Montgomery) and the craniofacial surgery team (Burstein, Cohen). Medical evaluation included physical examination, chest and cervical spine radiographs, testing to rule out gastroesophageal reflux, 12-lead electrocardiogram, cardiac ultrasonography, flexible upper airway endoscopy during spontaneous ventilation, com-

TABLE I  
Diagnostic Treatment Groups. Group I, Mixed; Group II, Down Syndrome; Group III, Cerebral Palsy; and Group IV, Goldenhar Syndrome

Group	Diagnosis	No. of Patients
I	Neurofibromatosis	1
I	Lymphangioma	1
I	Developmental delay	3
I	Pfeiffer's syndrome	1
I	Obesity	1
II	Down syndrome	5
III	Cerebral palsy	12
IV	Goldenhar syndrome	4
	TOTAL	28

puted axial tomography (CAT scan) of the head and neck, and whenever possible, lateral head cephalograms. Overnight 12-channel polysomnograms were obtained in all patients. Obstructive apnea is defined as complete cessation of ventilation. The apnea index, defined as the total number of apneic events divided by the total sleep time and multiplied by 60, was calculated from the sleep data. The respiratory disturbance index, defined as the number of apneas and hypopneas divided by the total sleep time and multiplied by 60, also was calculated. All patients had undergone maximal medical treatment without significant improvement before being entered in our treatment protocol. Statistical analysis of the preoperative and postoperative apnea index and respiratory disturbance index values was carried out.

#### SURGICAL PROCEDURES

All patients underwent a combination of procedures selected according to their sites of obstruction as defined by physical examination, endoscopy, and radiographic evaluation (Table II). Eight patients had previously undergone tonsillectomy and adenoidectomy for pre-

TABLE II  
Summary of Surgical Procedures

Surgical Procedure	No. of Patients
Tonsillectomy and adenoidectomy	16
Uvulopalatopharyngoplasty	25
Turbineotomy	16
Tongue reduction	5
Tongue-hyoid suspension	21
Maxillary advancement	1
Mandibular advancement	2
Mandibular construction	4
Distraction osteogenesis	2
TOTAL	92

