

Long-Term Experience with Endoscopic Surgical Treatment for Congenital Muscular Torticollis in Infants and Children: A Review of 85 Cases

Fernando D. Burstein, M.D.

Atlanta, Ga.

Congenital muscular torticollis is attributable to trauma or ischemic insults with fibrosis and subsequent shortening of the sternocleidomastoid muscle.^{1,2} The cause of the muscle damage may be birth trauma, shortening secondary head position in utero, or it may be residual in cases of pseudotumor coli.³ Skull deformities such as unilateral coronal or lambdoid synostosis may also be confused with torticollis, requiring radiographic examination for differentiation.^{4,5}

Over the last 10 years, the technique for endoscopic release of congenital muscular torticollis has evolved from our early experience, reported in 1998, to the current state.⁶ The current treatment protocol calls for early evaluation and treatment of the deformity. Physical therapy in a supervised environment is prescribed at the time of initial evaluation. If there is significant facial plagiocephaly, especially involving the frontal and orbital areas, a concomitant molding helmet is often prescribed. If the patient is refractory to these measures in terms of achieving full range of motion of the neck and having significant facial plagiocephaly, endoscopic release is offered to the family by 1 year of age.

PATIENTS AND METHODS

Patients

A total of 85 infants and children, 40 females and 45 males, ranging in age from 4 months to

2.5 years (mean age, 12 months), have undergone outpatient endoscopic sternocleidomastoid muscle release since 1996. Follow-up has ranged from 6 months to 8 years (mean follow-up, 36 months). All patients underwent a minimum of 3 months preoperative physical therapy, and molding helmets were prescribed for those cases also involving significant facial and cranial plagiocephaly. All patients had limitation of head rotation of at least 20 degrees, persistent head tilt, and craniofacial asymmetry.

Surgical Technique

The initial surgical technique was presented in 1998, and except for the refinements discussed in this section, it remains the same. Changes include the use of a single incision placed perpendicular to the long axis of the auricle in the hair-bearing scalp (Fig. 1). The great auricular nerve is the key endoscopic landmark; once it has been visualized, muscle transection begins, utilizing endoscopic scissors and spreading before cutting in the direction of the spinal accessory nerve (Fig. 2). The main branches of the spinal accessory nerve become visible during spreading and cutting of the muscle fibers (Fig. 3). The vertical branches are preserved to keep the proximal and distal portions of the muscle innervated. If the deepest portions of the muscle bundle are not involved in fibrosis, a thin sheet of muscle

From the Center for Craniofacial Disorders, Children's Healthcare of Atlanta, and the Division of Plastic and Reconstructive Surgery, Emory University. Received for publication August 25, 2003.

Follow-up to Burstein, F. D., and Cohen, S. R. Endoscopic surgical treatment for congenital muscular torticollis. *Plast Reconstr. Surg.* 101: 20, 1998.

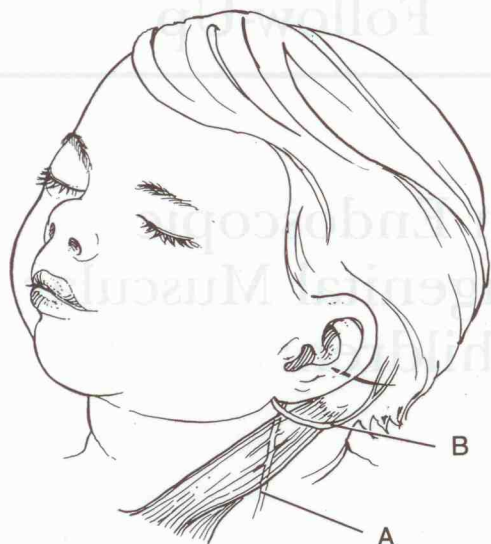


FIG. 1. Artist's drawing of important surgical landmarks. Note single incision perpendicular to long axis of ear. A, spinal accessory nerve below muscle; B, great auricular nerve.

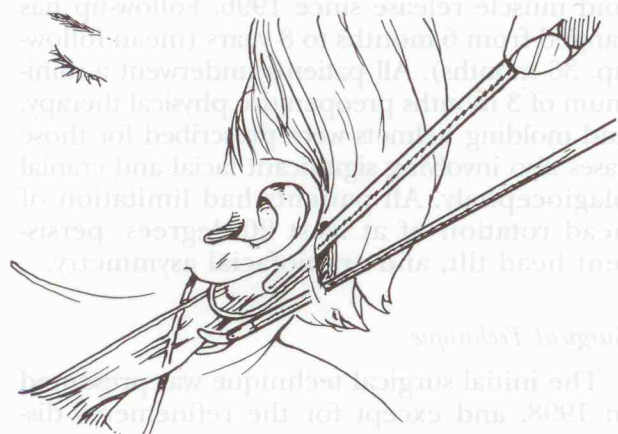


FIG. 2. Artist's drawing of endoscopic surgical release. Endoscopic scissors are being used, with magnified endoscopic visualization, to begin the muscle division below the great auricular nerve.

is preserved, covering the internal jugular vein and carotid sheath. This in no way compromises the muscle release.

RESULTS

With the exception of the previous reported adolescent patient who required a small skin incision to ligate a branch of the external jugular vein, there have been no complications.⁶ All patients achieved satisfactory neck range of motion results by the modified Ling method of classification.⁷ There were no injuries to the spinal accessory nerve. None of the patients who have been treated with our protocol have required surgery of the jaws or craniofacial

skeleton. All have achieved good facial and cranial symmetry with no gross occlusal abnormalities.

DISCUSSION

Untreated muscular torticollis can result in severe facial and cranial plagiocephaly.⁸ Occlusal abnormalities become apparent as patients reach adolescence and may require complex orthodontic and orthognathic surgical correction.^{9,10} Physical therapy is combined with a molding helmet in those cases in which there is frontal orbital and/or skull plagiocephaly.¹¹

When conservative therapy fails, endoscopic torticollis release offers significant advantages over the open techniques, including the absence of a visible scar, preservation of the innervation to the proximal and distal muscles, and the safety of magnification of all vital structures to ensure their preservation. No neck contour deformities have been seen, owing to preservation of innervation to the entire muscle.

Potential pitfalls, such as inadvertent great vessel injury or nerve injury, were of great concern at initiation of this technique. With increasing experience with this technique and with endoscopic plastic surgery in general, these concerns have not been realized. The endoscopic surgical approach is optimal in the infant and pediatric age groups and should be

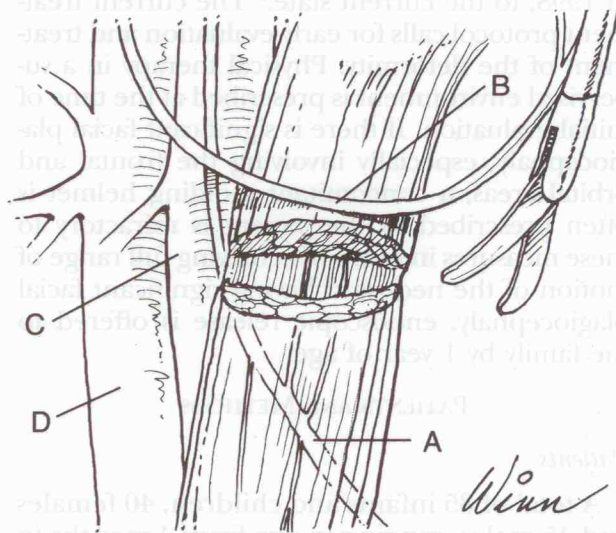


FIG. 3. Artist's drawing of important surgical anatomy for endoscopic muscle release. A, spinal accessory nerve with vertical branches preserved to proximal and distal muscle; B, great auricular nerve; C, internal jugular vein; D, carotid artery. Note preservation of thin sheet of normal muscle over great vessels.

