

# Hydroxyapatite Cement in Craniofacial Reconstruction: Experience in 150 Patients

Fernando D. Burstein, M.D.  
 J. Kerwin Williams, M.D.  
 Roger Hudgins, M.D.  
 William Boydston, M.D.,  
 Ph.D.  
 Andrew Reisner, M.D.  
 Kevin Stevenson, M.D.  
 Steven Cohen, M.D.  
*Atlanta, Ga.; and San Diego, Calif.*

The use of hydroxyapatite has become an accepted part of the craniofacial surgeon's armamentarium.<sup>1-3</sup> Hydroxyapatite was originally available as blocks, then as granules, and most recently as a powder that can be mixed with a catalyst to form a ceramic.<sup>4</sup> The original blocks were useful in filling bony gaps and as onlay grafts.<sup>2,5</sup> Their brittle nature and the difficulty in shaping them limited their application in the repair of orbitocranial defects. The granules could be molded and mixed with blood, thrombin, and methylcellulose to form a granular paste that could be used to fill in contour defects of the facial skeleton.<sup>6</sup> The lack of an adequate standardized carrier and particle migration when the granules were exposed to gravity made their use difficult. Both the blocks and granules exhibited pore sizes that allowed bony ingrowth and stable long-term results, with no significant loss of volume.<sup>1-3,5,6</sup> A powder form of hydroxyapatite has recently become available. When mixed with a catalyst, it forms a paste<sup>4,7</sup> that is easy to mould and cures quite rapidly to ceramic cement, thereby preventing gravitational effects. Our previous work with hydroxy-

apatite blocks and granules stimulated us to begin using the hydroxyapatite cement more than 7 years ago for a variety of orbitocranial applications.<sup>8,9</sup> Recent reports of high complication rates and unsatisfactory results with this material prompted us to review our experience.<sup>10,11</sup> In this report, we detail the indications, techniques for application, and limitations of hydroxyapatite cement.

### PATIENTS AND METHODS

One hundred fifty patients underwent orbitocranial reconstruction with hydroxyapatite cement over a 7-year period. The 85 male and 65 female patients ranged in age from 2.2 to 50 years old (mean age, 9.8 years). The majority of patients ( $n = 134$ ) had onlay application of hydroxyapatite cement for orbitocranial contour defects, while 16 patients underwent inlay application for full-thickness skull defects ranging in size from 1 cm to 7 cm. Mesh scaffolding was used in all inlay applications, with titanium mesh in 10 patients and resorbable mesh in six. The mesh scaffolding was placed between the dura and the hydroxyapatite cement (Figs. 1 and 2). The amount of hydroxyapatite cement paste ranged from 8 g to 125 g (mean, 26 gm). All patients were followed for a minimum period of 1 year (range, 1 to 7 years; mean, 26 months). Two different brands of hydroxyapatite cement were used in this study: Bone Source (Leibinger Corp., Kalamazoo, Mich.) in 70 patients and Mimix (W. Lorenz Surgical, Jacksonville, Fla.) in 80 patients.

Preoperative evaluation included computed tomography scanning, with three-dimensional reconstruction whenever possible. All patients were operated on under a general endotracheal anesthesia through previously existing coronal scars when present, which were excised in a W-plasty

*From the Center for Craniofacial Disorders and the Division of Neurosurgery, Children's Healthcare of Atlanta; Division of Plastic Surgery, Emory University; and San Diego Children's Hospital.*

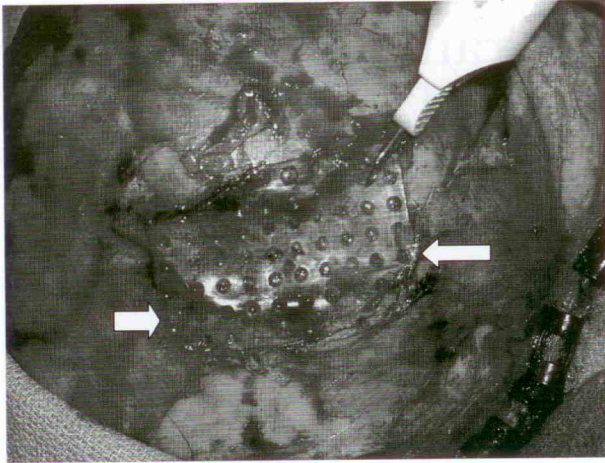
*Received for publication November 9, 2004; accepted April 19, 2005.*

*Follow-up to Burstein, F., Cohen, S. R., Hudgins, R., et al. The use of hydroxyapatite cement in secondary craniofacial reconstruction. Plast. Reconstr. Surg. 104: 1270, 1999. Presented at the 2004 International Craniofacial Society Congress, in Monterrey, California. September 21 through 24, 2003.*

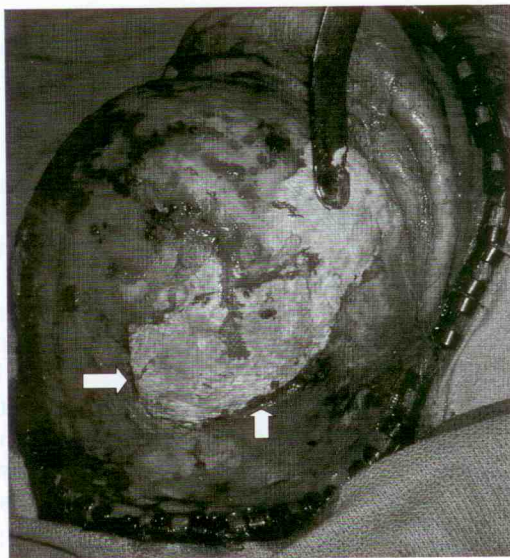*Copyright ©2006 by the American Society of Plastic Surgeons*

DOI: 10.1097/01.prs.0000234811.48147.64





**Fig. 1.** Intraoperative view of full-thickness skull defect with application of resorbable mesh superstructure (arrows). The suprastructure has been recessed to allow for the application of at least 5 mm of hydroxyapatite cement. A heat pen is used to trim redundant mesh.



**Fig. 2.** Intraoperative view of patient in shown in Figure 1. Hydroxyapatite cement is applied to the mesh suprastructure until it is flush with the surrounding bone. Arrows show the feathering of the cement onto the surrounding bone.

pattern. The areas of contour deficit or irregularities were carefully mapped and marked before injection of diluted bupivacaine and epinephrine. Subgaleal dissection was carried out, with as much of the periosteum preserved as possible, to expose the areas of interest. Once the area of interest was reached, a large flap of pericranium was elevated to expose the underlying skull. If the temporal areas were to be augmented, the temporalis mus-

cle was incorporated into the pericranial flaps. Any hardware that was present was removed, and all fibrous tissue was dissected off the underlying bone. All areas of protrusion were then contoured with a large cutting bone burr. The areas of hydroxyapatite cement application then had small furrows burred in a crisscross pattern, using a small diamond burr, to increase the area of hydroxyapatite cement adhesion. All bleeding points were hemocoagulated to avoid the use of bone wax.

The hydroxyapatite cement was mixed with cephalothin powder (1 g of cephalothin per 10 g of hydroxyapatite cement, up to 2 g of cephalothin) before it was added to the activator. Once a putty consistency was reached, the hydroxyapatite cement was applied to the areas of contoured skull, with a maximum of 25 g applied at one time. Each layer was textured with an open gauze sponge during the drying process, to create a thin crosshatching pattern on the surface of the cement, for better layer-to-layer adherence. The pericranial and scalp flaps were returned to their original position while the cement was still malleable for external pressure contouring. This process was repeated as required, with complete drying between layers, until the desired contour correction was achieved. The cement was kept at least 5 cm anterior to the scalp incision without overcorrection. All loose or fragmented cement was removed, final contouring with a large diamond burr was carried out, and the pericranium was then closed over the area of cement application. In the inlay cases, the recipient sites were prepared by contouring the edges of the full-thickness defects with a diamond burr and then applying a titanium mesh or resorbable mesh scaffold directly over the dura and securing the scaffold with screws to the surrounding skull (Figs. 1 and 2). The mesh scaffolding was contoured with heat to have a slight concavity before the application of hydroxyapatite cement to a thickness of at least 5 mm (Figs. 1 and 2). A closed vacuum drain was inserted, avoiding contact with the cement, and the scalp was closed in layers using resorbable sutures. All patients received 24 hours of intravenous cephalothin and 5 days of oral cephalothin. All drains were removed within 24 hours, and the patients were discharged home without a dressing.

## RESULTS

One hundred thirty-eight patients (92 percent) achieved satisfactory contour results (Figs. 3 through 7). There were 13 complications (9 percent), all in the onlay group. Seven patients had

