

Hydroxyapatite Cement in Craniofacial Reconstruction: Experience in 150 Patients

Fernando D. Burstein, M.D.

J. Kerwin Williams, M.D.

Roger Hudgins, M.D.

William Boydston, M.D.,

Ph.D.

Andrew Reisner, M.D.

Kevin Stevenson, M.D.

Steven Cohen, M.D.

Atlanta, Ga.; and San Diego, Calif.

The use of hydroxyapatite has become an accepted part of the craniofacial surgeon's armamentarium.¹⁻³ Hydroxyapatite was originally available as blocks, then as granules, and most recently as a powder that can be mixed with a catalyst to form a ceramic.⁴ The original blocks were useful in filling bony gaps and as onlay grafts.^{2,5} Their brittle nature and the difficulty in shaping them limited their application in the repair of orbitocranial defects. The granules could be molded and mixed with blood, thrombin, and methylcellulose to form a granular paste that could be used to fill in contour defects of the facial skeleton.⁶ The lack of an adequate standardized carrier and particle migration when the granules were exposed to gravity made their use difficult. Both the blocks and granules exhibited pore sizes that allowed bony ingrowth and stable long-term results, with no significant loss of volume.^{1-3,5,6} A powder form of hydroxyapatite has recently become available. When mixed with a catalyst, it forms a paste^{4,7} that is easy to mould and cures quite rapidly to ceramic cement, thereby preventing gravitational effects. Our previous work with hydroxy-

apatite blocks and granules stimulated us to begin using the hydroxyapatite cement more than 7 years ago for a variety of orbitocranial applications.^{8,9} Recent reports of high complication rates and unsatisfactory results with this material prompted us to review our experience.^{10,11} In this report, we detail the indications, techniques for application, and limitations of hydroxyapatite cement.

PATIENTS AND METHODS

One hundred fifty patients underwent orbitocranial reconstruction with hydroxyapatite cement over a 7-year period. The 85 male and 65 female patients ranged in age from 2.2 to 50 years old (mean age, 9.8 years). The majority of patients ($n = 134$) had onlay application of hydroxyapatite cement for orbitocranial contour defects, while 16 patients underwent inlay application for full-thickness skull defects ranging in size from 1 cm to 7 cm. Mesh scaffolding was used in all inlay applications, with titanium mesh in 10 patients and resorbable mesh in six. The mesh scaffolding was placed between the dura and the hydroxyapatite cement (Figs. 1 and 2). The amount of hydroxyapatite cement paste ranged from 8 g to 125 g (mean, 26 gm). All patients were followed for a minimum period of 1 year (range, 1 to 7 years; mean, 26 months). Two different brands of hydroxyapatite cement were used in this study: Bone Source (Leibinger Corp., Kalamazoo, Mich.) in 70 patients and Mimix (W. Lorenz Surgical, Jacksonville, Fla.) in 80 patients.

Preoperative evaluation included computed tomography scanning, with three-dimensional reconstruction whenever possible. All patients were operated on under a general endotracheal anesthesia through previously existing coronal scars when present, which were excised in a W-plasty

From the Center for Craniofacial Disorders and the Division of Neurosurgery, Children's Healthcare of Atlanta; Division of Plastic Surgery, Emory University; and San Diego Children's Hospital.

Received for publication November 9, 2004; accepted April 19, 2005.

Follow-up to Burstein, F., Cohen, S. R., Hudgins, R., et al. The use of hydroxyapatite cement in secondary craniofacial reconstruction. Plast. Reconstr. Surg. 104: 1270, 1999.

Presented at the 2004 International Craniofacial Society Congress, in Monterrey, California. September 21 through 24, 2003.

Copyright ©2006 by the American Society of Plastic Surgeons

DOI: 10.1097/01.prs.0000234811.48147.64

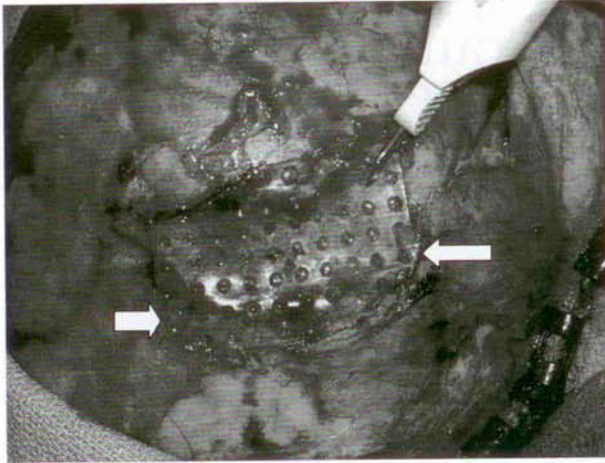


Fig. 1. Intraoperative view of full-thickness skull defect with application of resorbable mesh superstructure (arrows). The suprastructure has been recessed to allow for the application of at least 5 mm of hydroxyapatite cement. A heat pen is used to trim redundant mesh.

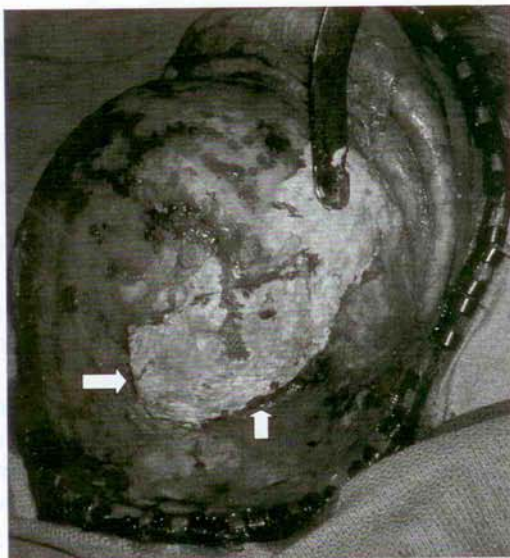

Fig. 2. Intraoperative view of patient in shown in Figure 1. Hydroxyapatite cement is applied to the mesh suprastructure until it is flush with the surrounding bone. Arrows show the feathering of the cement onto the surrounding bone.

pattern. The areas of contour deficit or irregularities were carefully mapped and marked before injection of diluted bupivacaine and epinephrine. Subgaleal dissection was carried out, with as much of the periosteum preserved as possible, to expose the areas of interest. Once the area of interest was reached, a large flap of pericranium was elevated to expose the underlying skull. If the temporal areas were to be augmented, the temporalis mus-

cle was incorporated into the pericranial flaps. Any hardware that was present was removed, and all fibrous tissue was dissected off the underlying bone. All areas of protrusion were then contoured with a large cutting bone burr. The areas of hydroxyapatite cement application then had small furrows burred in a crisscross pattern, using a small diamond burr, to increase the area of hydroxyapatite cement adhesion. All bleeding points were hemocoagulated to avoid the use of bone wax.

The hydroxyapatite cement was mixed with cephalothin powder (1 g of cephalothin per 10 g of hydroxyapatite cement, up to 2 g of cephalothin) before it was added to the activator. Once a putty consistency was reached, the hydroxyapatite cement was applied to the areas of contoured skull, with a maximum of 25 g applied at one time. Each layer was textured with an open gauze sponge during the drying process, to create a thin crosshatching pattern on the surface of the cement, for better layer-to-layer adherence. The pericranial and scalp flaps were returned to their original position while the cement was still malleable for external pressure contouring. This process was repeated as required, with complete drying between layers, until the desired contour correction was achieved. The cement was kept at least 5 cm anterior to the scalp incision without overcorrection. All loose or fragmented cement was removed, final contouring with a large diamond burr was carried out, and the pericranium was then closed over the area of cement application. In the inlay cases, the recipient sites were prepared by contouring the edges of the full-thickness defects with a diamond burr and then applying a titanium mesh or resorbable mesh scaffold directly over the dura and securing the scaffold with screws to the surrounding skull (Figs. 1 and 2). The mesh scaffolding was contoured with heat to have a slight concavity before the application of hydroxyapatite cement to a thickness of at least 5 mm (Figs. 1 and 2). A closed vacuum drain was inserted, avoiding contact with the cement, and the scalp was closed in layers using resorbable sutures. All patients received 24 hours of intravenous cephalothin and 5 days of oral cephalothin. All drains were removed within 24 hours, and the patients were discharged home without a dressing.

RESULTS

One hundred thirty-eight patients (92 percent) achieved satisfactory contour results (Figs. 3 through 7). There were 13 complications (9 percent), all in the onlay group. Seven patients had

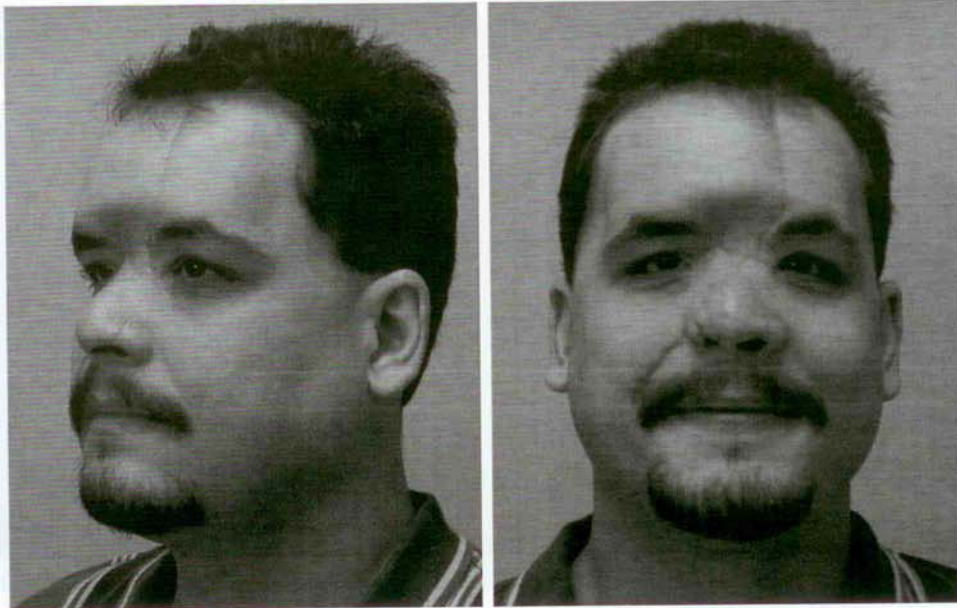

Fig. 3. Oblique and frontal views of patient after initial repair of facial/cranial gunshot wound at an outside institution. Note the severe frontal/orbital and temporal bone contour defects.

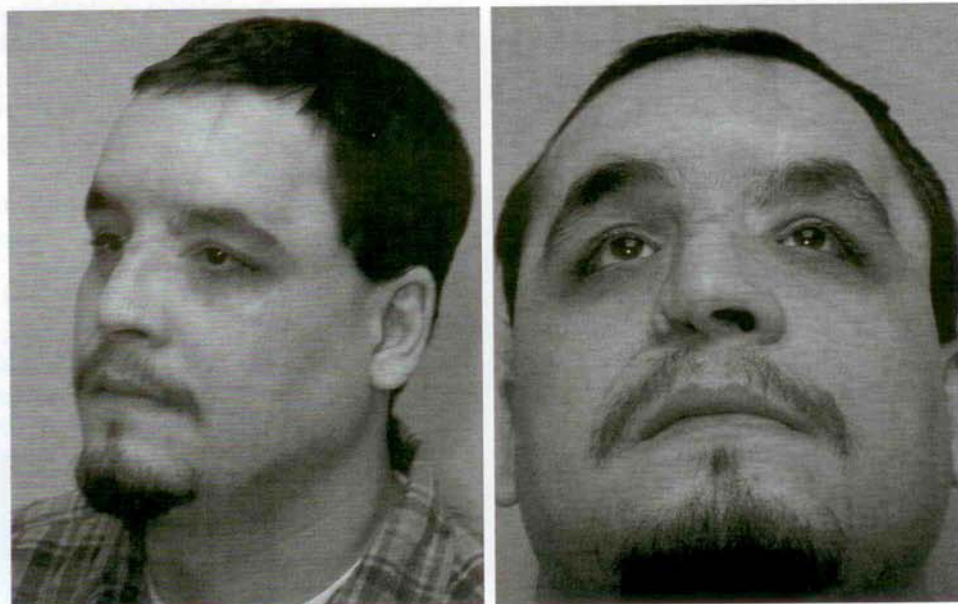

Fig. 4. Oblique and frontal views of patient shown in Figure 3, 1 year after bone contouring and onlay application of 75 g of hydroxyapatite cement and nasal reconstruction.

seromas within 1 week of surgery, requiring aspiration only. Four patients developed chronic seromas that were not responsive to repeated aspiration and pressure dressings. Three of these patients were returned to the operating room for removal of microfragmented hydroxyapatite cement and drain placement. One patient with a chronic seroma caused by traumatic fragmenta-

tion after a sports-related head trauma did not return for operative intervention. Intraoperative cultures and Gram stains were negative in all three patients who returned to the operating room for seromas, and all had uneventful recoveries without loss of contour correction. One patient required operative intervention when the drain became adherent to the cement. One patient had

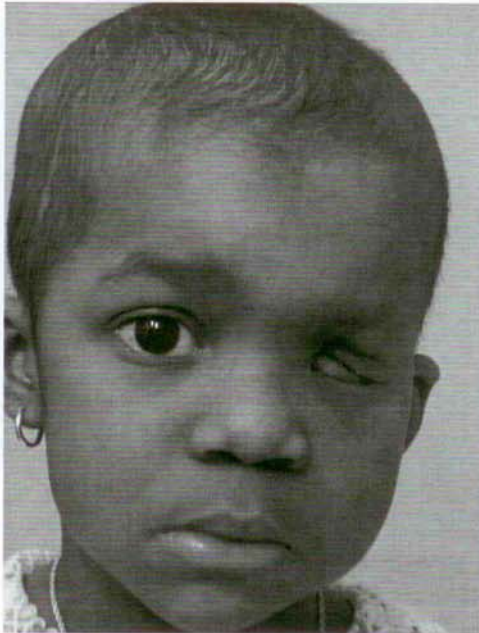

Fig. 5. Preoperative view of patient after enucleation and resection of frontal bone, lateral orbit, and partial maxillectomy for orbital sarcoma.




Fig. 6. Postoperative view of patient shown in Figure 5, 3 years after inlay and onlay reconstruction of submental bone and orbit with 100 g of hydroxyapatite cement. An orbital conformer has been fitted to the reconstructed orbit.

overcorrection of the orbit and required secondary contouring. All but one of the complications occurred in our initial 70 patients. There were no complications in the inlay group.

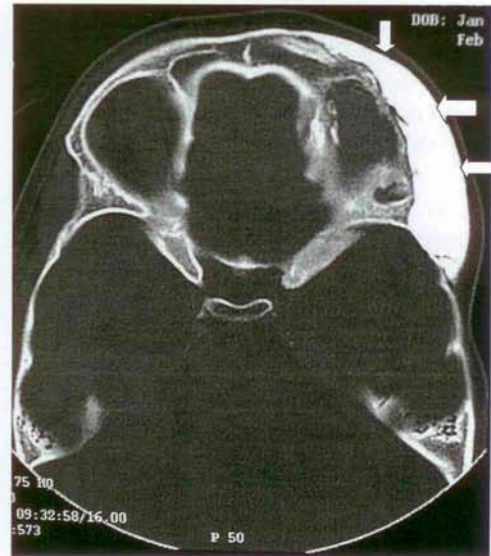


Fig. 7. Computed tomography scan of patient shown in Figures 5 and 6, demonstrating intact hydroxyapatite cement in the lateral orbit and temporal bone 3 years after application.

DISCUSSION

The use of hydroxyapatite blocks in craniofacial surgery demonstrated a novel application of a biointegratable implant derived from a naturally occurring compound.^{1-3,9} The pore sizes allowed for ingrowth of bone, creating a stable bone hydroxyapatite matrix.⁵ Despite this osseointegration, the inherently brittle nature of the blocks prevented their use in load-bearing applications. Contouring of these brittle blocks was difficult, and an edge effect was often visible if the block was placed close to the skin. Hydroxyapatite granules, with pore sizes similar to those of the blocks, then became available.^{5,12} These granules could be applied to fill irregular contour defects as long as a periosteal pocket could be created.^{6,12} We later combined the granules with blood and resorbable collagen to create slurry, which was much easier to apply than dry granules.⁶ This allowed the hydroxyapatite to be applied to areas such as the frontal bone, where a completely closed pocket was not possible. We found that the granules became osseointegrated while retaining their volume. This technique, although it extended the applications for granular hydroxyapatite, had inherent limitations. The curing period was prolonged and unpredictable, because consolidation depended on adherence of the granules to the underlying bed and to each other. The exact volume after consolidation was difficult to predict, which often led to overfilling and underfilling of contour defects. Gravitational forces would occasionally result in settling of the granules, which created pro-

trusions. The introduction of hydroxyapatite cement as a powder that could be mixed with a catalyst to rapidly form a stable ceramic made application much easier and the end result more predictable.⁴ The resulting paste could be sculpted to create any desired shape, which was stable volumetrically.⁸ The pore size of the dried paste was smaller than the pore size of the granular form and, in our experience, resulted in less penetration of the surrounding bone into the cement. Over time, bone islands formed on the surface of the material as well as between the cement and the surrounding bony borders (Figs. 8 and 9). Volume and contour were stable. In addition, the hydroxyapatite cement paste was very easy to mould and could be used to fill irregular contour defects without requiring a periosteal envelope for containment. The addition of cephalosporin powder to the hydroxyapatite cement powder did not appreciably affect the properties of the final cement, while providing a locally released antibiotic prophylaxis.^{13,14} The curing times, malleability, and adherence of hydroxyapatite cement were not notably affected by the addition of powdered antibiotics. We did not find a significant difference between the two brands of cement we tested in terms of final result or rate of complications. Each product had different handling characteristics, but both cured quickly and completely.

Eppley,¹⁵ Costantino et al.,¹⁶ and others¹⁷ have reported favorable clinical results using hydroxyapatite cement for orbitocranial reconstruction. Magee et al.¹⁸ recently reported excellent results in a series of 48 patients with contour irregularities treated with hydroxyapatite cement mixed with cephalothin. No clinical or experimental evidence

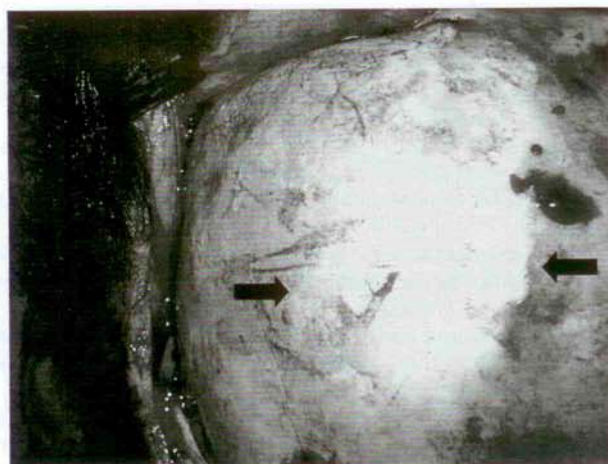

Fig. 8. Intraoperative view of onlay hydroxyapatite cement at skull site 4 years after application. Arrows delineate areas of ingrowth of surrounding bone over the cement.

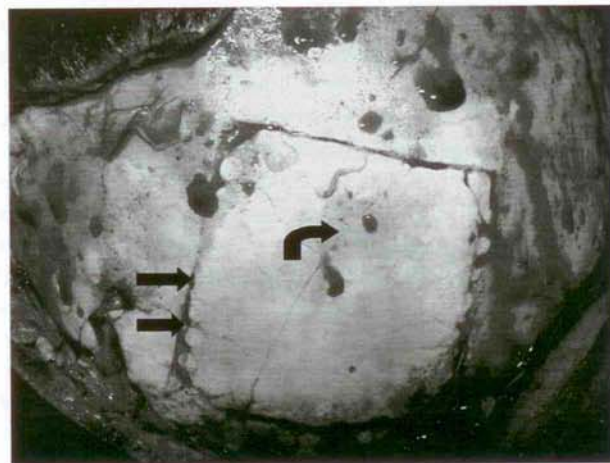


Fig. 9. Intraoperative view of inlay hydroxyapatite cement at skull site 3 years after application. Straight arrows identify the interface among the skull, resorbable plate, and cement. The curved arrow points to the bone island on the surface of the hydroxyapatite cement.

to date has shown a deleterious effect on the growing craniofacial skeleton.^{8,9,18,19}

Durham et al., Moreira-Gonzales et al., Matic and Phillips, and others have reported high complication rates in orbitocranial reconstruction.^{10,11,20-23} Complications ranged from fragmentation to implant exposure and infection. We speculate that that the apparent discrepancy in success rates reported by various authors can be explained on the basis of clinical indications and technique. Authors reporting favorable outcomes tended to use smaller amounts of hydroxyapatite cement and avoided using the cement in the paranasal sinuses or in areas of cerebrospinal fluid leakage. Adequate soft-tissue coverage and placement in non-stress-bearing areas was noted in their series. In contrast, authors who reported high complication rates often applied large amounts of hydroxyapatite cement and may have had thin soft-tissue coverage or previous radiation damage to the overlying soft tissues.

The most frequent complication we encountered was seroma formation. In all of the chronic seromas that required exploration, we found microfragmentation of the hydroxyapatite cement localized to the area of the seroma. In these cases, only the loose fragments were removed and the edges of the hydroxyapatite cement were beveled with a diamond burr. Other authors have also reported this problem, which in most studies was associated with infection and required removal of the hydroxyapatite cement.^{20,21} We believe that microfragmentation and seroma formation are part of the same process. Fragmentation is due to technical factors, such as improper curing and poor adherence of the hy-

droxyapatite cement to the underlying bone or between the cement layers. The fragments can result in an inflammatory reaction, leading to seroma formation. If they are not aggressively drained, these seromas can become chronic and, in some cases, secondarily infected. On the basis of our experience, we recommend prompt evacuation of any seromas, and if the seromas are persistent, we recommend operative intervention. All fragments should be removed, and antibiotic irrigation as well as drainage is recommended concurrent with antibiotic treatment based on culture results. Aggressive treatment of seromas prevented loss of the hydroxyapatite cement contouring in our series. Infection may also be due to implant exposure, contamination, or inadequate soft-tissue coverage. Proper recipient bed preparation, complete curing of each layer of the cement, and texturing between layers has largely eliminated seromas caused by fragmentation in our practice. Interestingly, the inlay patients in whom the cement was used with a mesh scaffolding did not experience fragmentation.

This study represents the largest series to date detailing indications and outcomes of hydroxyapatite cement application in orbitocranial surgery. We believe that the success of our series can be attributed to several technical points: avoidance of contact with the paranasal sinuses, avoidance of oral exposure, incorporation of antibiotics into the hydroxyapatite cement, limiting the amount of material used, careful recipient-site preparation, adequate soft-tissue coverage of the hydroxyapatite cement, and aggressive drainage and débridement of seromas. The fact that almost all of our complications occurred early in our experience reflects the learning curve necessary for successful application of a new technique. Hydroxyapatite cement is a useful and versatile material that can be used safely as an inlay or onlay in the orbitocranial area. It is not a stress-bearing material. Care must be taken in recipient-site selection and technical application to avoid complications. Hydroxyapatite cement can be coupled with resorbable or titanium mesh in inlay applications, which appears to increase structural integrity.

Fernando D. Burstein, M.D.
 Division of Plastic Surgery
 Emory University
 Suite 500
 975 Johnson Ferry Road
 Atlanta, Ga. 30342
 fburstein@aol.com
 dromagna@atlplastic.com

REFERENCES

1. Salyer, K. E., and Hall, C. D. Porous hydroxyapatite as an onlay bone-graft substitute for maxillofacial surgery. *Plast. Reconstr. Surg.* 84: 236, 1989.
2. Rosen, H. M. Porous block hydroxyapatite as an interpositional bone graft in orthognathic surgery. *Plast. Reconstr. Surg.* 83: 985, 1989.
3. Habal, M. B., and Reddi, A. H. Bone grafts and bone induction substitutes. *Clin. Plast. Surg.* 21: 525, 1994.
4. Ishikawa, K., Takagi, S., Chow, L., et al. Properties and mechanisms of fast setting calcium phosphate cements. *J. Mater. Sci. Mater. Med.* 6: 528, 1995.
5. Kent, J., Zide, M., Kay, J., et al. Hydroxyapatite blocks and particles as bone graft substitutes in orthognathic and reconstructive surgery. *J. Oral Maxillofac. Surg.* 44: 597, 1986.
6. Burstein, F. D., Cohen, S. R., Hudgins, R., et al. The use of porous granular hydroxyapatite in secondary orbitocranial reconstruction. *Plast. Reconstr. Surg.* 100: 869, 1997.
7. Friedman, C. D., Costantino, P. D., Jones, K., et al. Hydroxyapatite cement: II. Obliteration and reconstruction of the cat frontal sinus. *Arch. Otolaryngol. Head Neck Surg.* 117: 385, 1991.
8. Burstein, F., Cohen, S. R., Hudgins, R., et al. The use of hydroxyapatite cement in secondary craniofacial reconstruction. *Plast. Reconstr. Surg.* 104: 1270, 1999.
9. Burstein, F. Use of bone substitutes in craniofacial reconstruction. *Perspect. Plast. Surg.* 15: 93, 2001.
10. Stankiewicz, J., Vady, A., Chow, J., et al. Complications of hydroxyapatite use for transnasal closure of cerebrospinal fluid leaks. *Am. J. Rhinol.* 16: 337, 2002.
11. Durham, S., McComb, J., and Levy, M. Correction of large cranial defects with reinforced hydroxyapatite cement: Technique and complications. *Neurosurgery* 52: 842, 2003.
12. Byrd, H., Hobar, C. P., and Shewmake, K. Augmentation of the craniofacial skeleton with porous hydroxyapatite granules. *Plast. Reconstr. Surg.* 91: 15, 1993.
13. Yu, D., Wong, J., Matsuda, Y., et al. Self-setting hydroxyapatite cement: A novel skeleton drug-delivery system for antibiotics. *J. Pharm. Sci.* 81: 529, 1992.
14. Tung, I. C. In vitro drug release of antibiotic loaded porous hydroxyapatite cement. *Artif. Cells Blood Substit. Immobil. Biotechnol.* 23: 81, 1995.
15. Eppley, B. L. Hydroxyapatite cranioplasty: 2 clinical experiences with a new quick-setting material. *J. Craniofac. Surg.* 14: 209, 2003.
16. Costantino, P. D., Chaplin, J. M., Wolpo, M. E., et al. Applications of fast-setting hydroxyapatite cement: Cranioplasty. *Otolaryngol. Head Neck Surg.* 123: 409, 2000.
17. Stelnicki, E. J., Hoffman, W. Y., and Ousterhout, D. K. A method for repairing zygomatic arch fractures using a hydroxyapatite cement paste. *J. Craniofac. Surg.* 8: 236, 1997.
18. Magee, W. P., Ajkay, N., and Freda, N. Use of fast-setting hydroxyapatite cement for secondary craniofacial contouring. *Plast. Reconstr. Surg.* 114: 289, 2004.
19. Lorenz, R. R., Papay, F. A., Barthel, S. W., et al. Hydroxyapatite cement reconstruction in the growing craniofacial skeleton: An experimental model. *J. Craniofac. Surg.* 13: 802, 2002.
20. Moreira-Gonzales, A., Jackson, I. T., Miyawaki, T., et al. Clinical outcome in cranioplasty critical review in long term follow up. *J. Craniofac. Surg.* 14: 144, 2003.
21. Matic, D., and Phillips, J. H. A contraindication for the use of hydroxyapatite cement in the pediatric population. *Plast. Reconstr. Surg.* 110: 1, 2002.
22. Stankiewicz, J. A., Vady, A. M., Chow, J. M., et al. Complications of hydroxyapatite use for transnasal closure of cerebrospinal fluid leaks. *Am. J. Rhinol.* 16: 337, 2002.
23. Mahendran, S., and Yung, M. W. Mastoid obliteration with hydroxyapatite cement: The Ipswich experience. *Otol. Neurotol.* 25: 19, 2004.