

Endoscopic Surgical Treatment for Congenital Muscular Torticollis

Fernando D. Burstein, M.D., and Steven R. Cohen, M.D.

Atlanta, Ga.

Muscular torticollis, if untreated, may result in significant permanent craniofacial deformities. Surgical release of the sternocleidomastoid muscle is recommended for patients who fail to respond to physical therapy. Current surgical techniques all leave noticeable scars, and provide limited exposure. These limitations make complete muscular release and visualization of the spinal accessory nerve difficult. We have applied a new technique of endoscopic release of the sternocleidomastoid muscle in 12 infants and children ages 4 to 18 months and one adolescent with muscular torticollis. Complete muscular release was achieved in all patients with one minor complication. The spinal accessory nerve was preserved in all cases. Our endoscopic approach allows precise division of the muscle fibers and preservation of neurovascular structures, leaving an inconspicuous scar in the scalp. (*Plast. Reconstr. Surg.* 101: 20, 1998.)

Torticollis, "wry neck," may be caused by various conditions.¹ Several generalized or localized neurologic conditions may trigger the spinal accessory nerve to fire and cause contraction of the sternocleidomastoid muscle resulting in spasmodic torticollis.^{2,3} Extraocular muscle imbalance may lead to compensatory head tilting, ocular torticollis.⁴ Unilateral coronal or lambdoid synostosis may be confused with torticollis, but can be diagnosed by physical examination and if necessary radiographic studies.⁵ Positional head deformities can be differentiated from torticollis by history and physical examination and are treated with positioning and, in some cases, with a molding helmet.⁶ Congenital muscular torticollis is due to muscle trauma or ischemia, with fibrosis and subsequent shortening of the sternocleidomastoid muscle.^{7,8} Rarely the trapezius and paraspinal muscles may also be involved.⁹ The etiology of the muscle damage may be birth

trauma, head position in utero, or be residual in cases of pseudo tumor colli.^{7,10} Muscular torticollis can cause severe limitations of neck position and, over time, may result in significant craniofacial deformation.¹¹

Congenital muscular torticollis can often be treated by nonsurgical means using physical therapy techniques aimed at gradual restoration of muscle length.¹² Surgical intervention is reserved for those patients that fail to respond to physical therapy, have a worsening of their facial deformities or severe neck angulation.^{1,9} Various surgical approaches have been advocated to release, lengthen, or excise a segment of the sternocleidomastoid muscle (Fig. 1).¹³

All techniques involve making an incision in the facial or neck skin with a resulting visible scar. The emergence of endoscopically assisted surgery has provided an important clinical tool, which we have applied to surgery for torticollis.^{14,15} In developing our technique our goals were to avoid any visible scars, achieve a complete release of the shortened muscle, and visualize key anatomic structures to avoid damaging them. We present our technique for endoscopic release of the sternocleidomastoid in infants and children.

MATERIALS AND METHODS

Twelve infants and children (ages 4 to 18 months; mean, 10.5 months; 7 boys, 5 girls) and one teenager (age, 14 years; girl) underwent outpatient endoscopic sternocleidomastoid muscle release under general anesthesia, over a 2-year period. Follow-up ranged from 6 to 24 months (mean, 14 months). All patients underwent a minimum of 3 months of preop-

From the Division of Plastic Surgery, Scottish Rite Children's Medical Center. Received for publication November 2, 1996; revised February 3, 1997.

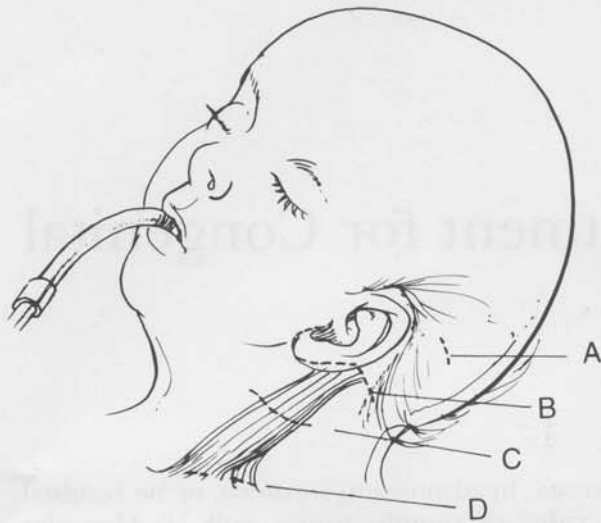


FIG. 1. Drawing of child with various surgical incisional approaches marked with dotted lines. (A) Scalp incision for endoscopic approach. (B) Postauricular incision for superior pole release. (C) Incision for mid muscular transection. (D) Supraclavicular incision used for lower pole release or lower part of bipolar release.

erative intensive neck range of motion exercises under the supervision of a certified physical therapist and were referred for surgery only after no further progress could be achieved. All had limitation of head rotation of at least 20 degrees, persistent head tilt, and craniofacial asymmetry.

Surgical Technique

A 5-mm endoscope, minicam with adapter and standard endoscopic ergonomic grip, graspers, scissors, and endoscopic suction cautery were used for all operative cases. The sternocleidomastoid muscle, angle of mandible, and mastoid were identified and marked in all patients (Fig. 2). Dilute lidocaine 0.25% with 1:400,000 epinephrine was injected along the operative site in the subcutaneous plane to help elevate the skin flap. A single transverse incision 1.5 to 2 cm in length was made well within the hair-bearing scalp at the level of the superior helical rim perpendicular to a line along the long axis of the sternocleidomastoid muscle (Fig. 1). Scissors dissection was used to elevate a skin flap over the muscle fascia, under direct vision, extending approximately 2 cm below the level of the greater auricular nerve, clearly identifying the anterior and posterior muscle borders (Fig. 2). With the greater auricular nerve identified, the muscle transection is initiated with endoscopic scissors dissection 1 cm below the greater auricular nerve (Fig. 3).

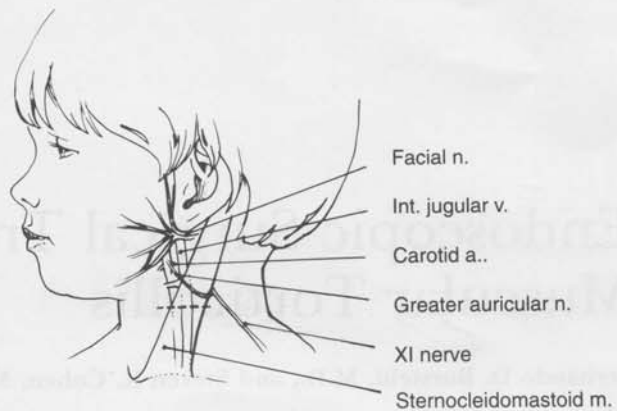


FIG. 2. Drawing of child demonstrating the relevant surgical anatomy. Dotted line indicates lowest point of dissection. Note the close proximity of the facial nerve to the superior pole of the muscle.

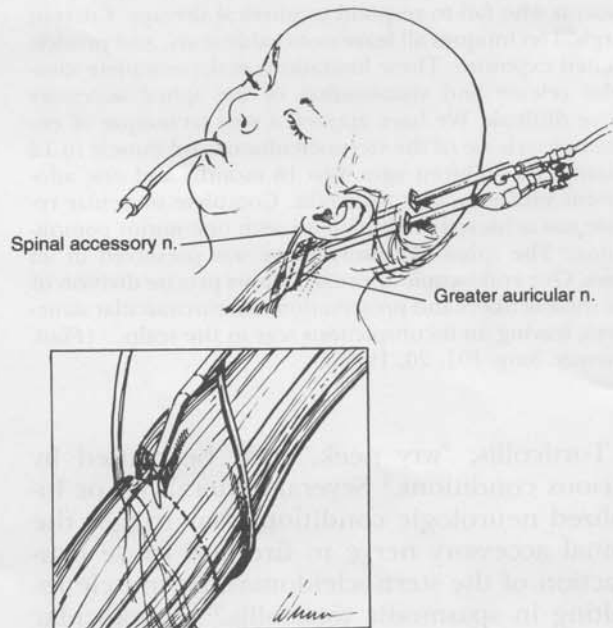


FIG. 3. Drawing of child in operating position. One or two scalp incisions can be used, although we prefer a single port. The endoscope is placed along the long axis of the muscle and serves to visualize the dissection and to hold up the skin flap. The insert demonstrates the relationship between the greater auricular nerve, above the muscle, and the spinal accessory nerve, within the muscle.

The spinal accessory nerve is encountered as it passes from medial to lateral approximately half-way through the muscle thickness (Figs. 3 through 5). The muscle transection continues first on the lateral, then on the medial side, of the nerve until the anterior and posterior muscle borders are reached and released. The deep muscle transection is complete when there are no further muscle fibers to cut, with the carotid artery and jugular vein being the

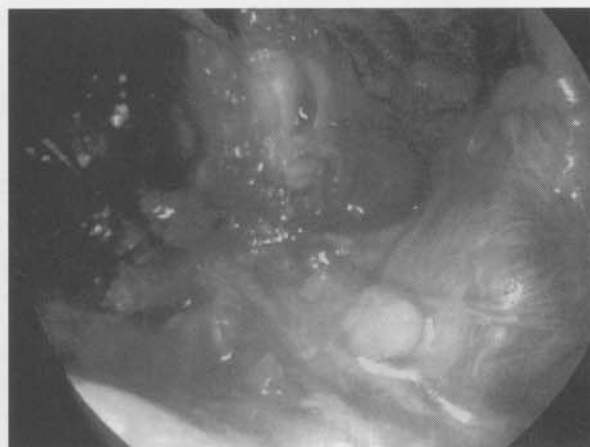
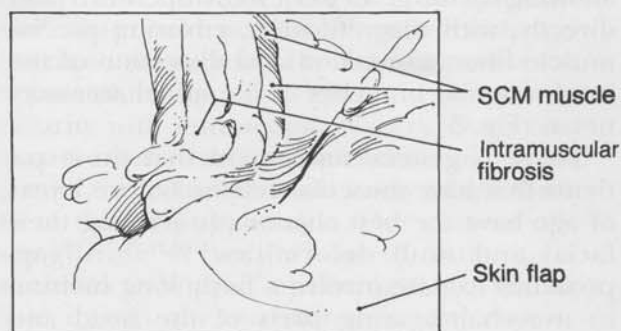


FIG. 4. (Left) Line drawing of endoscopic view, seen at right, with landmarks labeled. SCM, sternocleidomastoid. (Right) Endoscopic operative view of sternocleidomastoid muscle. The area of muscular fibrosis is in the middle of the photograph with the tip of the endoscopic scissors visible along the superior left muscle border.

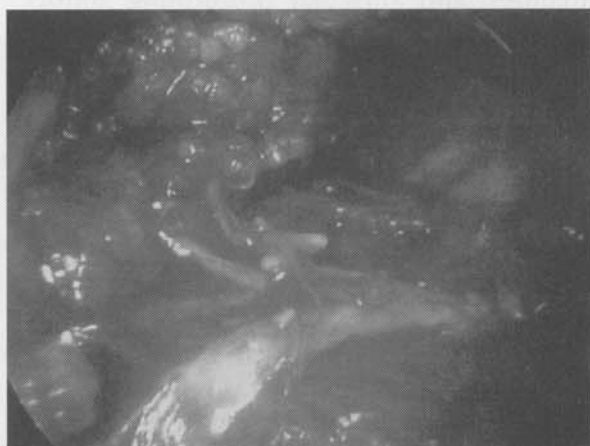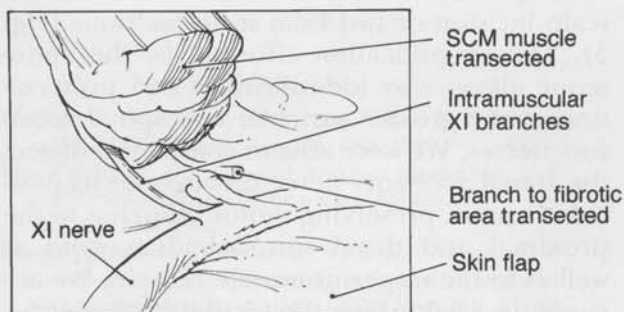


FIG. 5. (Left) Line drawing of endoscopic view seen at right, demonstrating course and intramuscular branches of spinal accessory nerve. SCM, sternocleidomastoid. (Right) Endoscopic operative view of partly transected muscle, top of photograph, and dissected spinal accessory nerve. Note numerous nerve branches to sternocleidomastoid muscle.

“floor” of the dissection (Fig. 2). The wound is then irrigated with antibiotic solution, the spinal accessory nerve electrically stimulated to confirm its continuity, and the wound closed with absorbable sutures. A single dose of intravenous cephalosporin is given during the operation. A soft cervical collar is applied and worn for 5 to 7 days. Active and passive neck range of motion exercises are instituted at 1 week and continued for 4 to 6 weeks after surgery.

RESULTS

All patients achieved good to excellent results by the modified Ling method of classification.¹⁶ Complete muscular release, as determined by intraoperative and postoperative neck range of motion measurements, was achieved in all cases. There were no cases of

infection, hematoma, loss of neck contour, or recurrent muscular bands. There were no injuries to the spinal accessory nerve. The scalp incisions healed without alopecia or scar hypertrophy in all cases. The relatively short follow-up period in this study does not allow us to draw any objective conclusions regarding the final outcome of the craniofacial deformities in the infants and children we treated. The 14-year-old female patient later underwent bimaxillary surgery for the correction of her fixed facial skeletal deformity. We encountered one intraoperative complication. The 14-year-old female patient with long-standing torticollis required a small direct incision on her neck to ligate a branch of the external jugular vein that was partially transected during the endoscopic approach. The intraoperative blood loss was under 5 ml in all of the other cases.

DISCUSSION

Torticollis is a descriptive name for a condition that may have a variety of causes.¹ In several of these conditions such as ocular and spasmodic torticollis the sternocleidomastoid muscle is completely normal anatomically but contracts in response to other physiologic abnormalities.²⁻⁴ In true muscular torticollis the muscle fibers themselves have been affected by in utero positioning, birth trauma, or other event leading to fibrosis and shortening of a portion of the muscle.^{7,9} Pseudotumor of infancy is a variant in which the damaged muscle presents as fibrotic mass.¹⁰ Left untreated, true muscular torticollis can result in a variety of permanent craniofacial deformities including plagiocephaly, facial asymmetry, occlusal abnormalities, and auricular positioning abnormalities.^{11,16,17} Early physical therapy, optimally before 6 months of age, has been shown to be successful in over 80 percent of cases.^{12,18,19} Adjuvant measures such as molding helmet therapy, halo devices, and adjustable cervical collars have been advocated with variable rates of success.^{6,20}

In cases that fail conservative therapy, surgical release of the sternocleidomastoid is recommended.¹ Numerous procedures have been advocated, including release at the tendinous attachments of the muscle to the mastoid and or clavicle, stair-step lengthening of the muscle or tendinous clavicular insertion, transection at one or more points of the muscle body, and partial or complete excision of the muscle.^{1,5,21,22} There is a paucity of information regarding complications such as damage to the greater auricular or spinal accessory nerves, encountered with any of these approaches. Ferkel et al. advocate a bipolar release with an inferior Z-plasty of the sternocleidomastoid tendon and reported this approach as being superior to other methods in a retrospective review.²⁴ We would caution that any of the procedures, such as that of Ferkel et al., that involve release of the sternocleidomastoid at the mastoid level could jeopardize the facial nerve when performed on an infant in whom the mastoid is not yet pneumatized (Fig. 2).²⁴ Common problems with current techniques are visible scars, recurrent muscle band formation, and loss of neck contour.^{16,24} We believe that these problems are due to incomplete initial release and denervation of the sternocleidomastoid muscle, respectively. The endo-

scopic approach avoids these problems by allowing the surgeon to view the operative field directly, with magnification, ensuring precise muscle fiber transection and dissection of the intramuscular branches of the spinal accessory nerve (Fig. 5).

There is general agreement that those patients that have muscular release before 1 year of age have the best chance of reversing their facial and skull deformities.^{1,19,21,22} All approaches to date involve a fairly long incision in non-hair-bearing parts of the head and neck (Fig. 1). Kawamoto reported his technique using the posterior limb of a face lift incision in 1985.⁵ We found this to be the most cosmetically favorable of the open approaches, but the occasional prominent scar line led us to the endoscopic scalp approach. This technique eliminates visible scarring and can be accomplished through a single 1.5- to 2.0-cm scalp incision or two 1-cm scalp incisions (Fig. 3). The magnification afforded by the endoscope allows easy identification and preservation of the greater auricular and spinal accessory nerves. We were able to completely dissect the spinal accessory nerve throughout its muscular course, preserving motor branches to the proximal and distal sternocleidomastoid as well as to the trapezius muscle (Fig. 5). We are currently establishing the feasibility of selective endoscopic rhizotomy for spasmodic torticollis.²⁶ Complete muscle transection is ensured by visualizing the anterior and posterior muscle edges as well as the underlying carotid artery and jugular vein. We found that this technique was easiest in infants because of the short working distances that were easily within reach of our instruments. In older children the instruments were barely adequate in their reach. This problem will require the development of instruments with longer working distances.

Potential problems with this technique are the same as those found with other endoscopic procedures including working while looking at the screen rather than the patient, limited instrumentation, a small optical cavity, and difficulty with smoke produced by electrocoagulation as well as fluid evacuation.^{14,15} Potential pitfalls of our endoscopic approach include damage to the carotid artery, jugular vein, or vagus nerve if the dissection is carried too deep, which would require an emergent open neck approach. We had to make a small neck incision in the one teenager in whom an en-

endoscopic muscle release was performed due to partial transection of the external jugular branch that could not be controlled with the endoscopic coagulator. The learning curve of this procedure depends upon the surgeon's familiarity with endoscopic surgery. Surgeons who are comfortable with endoscopic brow and midface techniques will easily adapt their skills to this new application. Our current operating time is very close to our open "Kawamoto technique" operating time.⁵ We attribute this to our increasing surgical experience and to the improving familiarity of the operating room staff with the endoscopic equipment. We feel that this is an exciting and very useful application in the rapidly emerging field of pediatric endoscopic surgery.

Fernando D. Burstein, M.D.

The Center For Craniofacial Disorders
5455 Meridian Mark Road, Suite 200
Atlanta, Ga. 30342

REFERENCES

1. Wolfort, F. G., Kanter, M. A., and Miller, L. B. Torticollis. *Plast. Reconstr. Surg.* 84: 682, 1989.
2. Van Zandijcke, M. Cervical dystonia (spasmodic torticollis): Some aspects of the natural history. *Acta Neurol. Belg.* 95: 210, 1995.
3. Turgut, M., Akalan, N., Bertan, V., et al. Acquired torticollis as the only presenting symptom in children with posterior fossa tumors. *Childs Nerv. Syst.* 11: 86, 1995.
4. Goodman, C. R., Chabner, E., and Guyton, D. L. Should early strabismus surgery be performed for ocular torticollis to prevent facial asymmetry? *J. Pediatr. Ophthalmol. Strabismus* 32: 162, 1995.
5. Kawamoto, H. R. Torticollis Versus Plagiocephaly. In D. Marchac (Ed.), *Craniofacial Surgery, Proceedings of the First International Congress of The International Society of Cranio-Maxillo-Facial Surgery*. Berlin: Springer-Verlag, 1987. Pp. 105-109.
6. Clarren, S. K., Smith, D. W., and Hanson, J. W. Helmet treatment for plagiocephaly and congenital muscular torticollis. *J. Pediatr.* 94: 43, 1979.
7. Davids, J. R., Wenger, D. R., and Mubarak, S. J. Congenital muscular torticollis: Sequella of intrauterine or perinatal compartment syndrome. *J. Pediatr. Orthop.* 13: 141, 1993.
8. Gonzales, J., Ljung, B.-M., Guerry, T., et al. Congenital torticollis: Evaluation by fine needle aspiration biopsy. *Laryngoscope* 99: 651, 1989.
9. Lawrence, W. T., and Azizkhan, R. G. Congenital muscular torticollis: a spectrum of pathology. *Ann. Plast. Surg.* 23: 523, 1989.
10. Porter, S. B., and Blount, B. W. Pseudotumor of infancy and congenital muscular torticollis. *Am. Fam. Physician* 52: 1731, 1995.
11. Ferguson, J. W. Surgical correction of the facial deformities secondary to untreated congenital muscular torticollis. *J. Craniomaxillofac. Surg.* 21: 137, 1993.
12. Emery, C. The determinants of treatment duration for congenital muscular torticollis. *Phys. Ther.* 74: 921, 1994.
13. Akazawa, H., Nakatsuka, Y., Miyake, Y., et al. Congenital muscular torticollis: Long term follow up of thirty-eight partial resections of the sternocleidomastoid muscle. *Arch. Orthop. Trauma Surg.* 112: 205, 1993.
14. Eaves, F., Price, C., Bostwick, J., et al. Subcutaneous endoscopic plastic surgery using a retractor mounted endoscopic system. *Perspect. Plast. Surg.* 7: 1, 1993.
15. Ramirez, O. M. Endoscopic techniques in facial rejuvenation: An overview. Part I. *Aesthetic Plast. Surg.* 18: 141, 1994.
16. Ling, C. M. The influence of age on the results of open sternomastoid tenotomy in muscular torticollis. *Clin. Orthop.* 116: 142, 1976.
17. Slate, R. K., Posnick, J. C., Armstrong, D. C., et al. Cervical spine subluxation associated with congenital muscular torticollis and craniofacial asymmetry. *Plast. Reconstr. Surg.* 91: 1187, 1993.
18. Canale, S. T., Griffin, D. W., and Hubbard, C. N. Congenital muscular torticollis: A long-term follow-up. *J. Bone Joint Surg. Am.* 64: 810, 1982.
19. Binder, H., Eng, G. D., Gaiser, J. F., et al. Congenital muscular torticollis: Results of conservative management with long-term follow-up in 85 cases. *Arch. Phys. Med. Rehabil.* 68: 222, 1987.
20. Armstrong, D., Pickrell, K., Fetter, B., et al. Torticollis: An analysis of 271 cases. *Plast. Reconstr. Surg.* 35: 14, 1965.
21. Petkovic, L., Pajic, D., Bajic, L., et al. Dynamic thermoplastic cervico-thoracic orthoses in conservative and postoperative treatment of congenital torticollis. *Med. Pregl. (Yugoslavia)* 47: 200, 1994.
22. Minamitani, K., Inoue, A., and Okuno, T. Results of surgical treatment of muscular torticollis for patients greater than 6 years of age. *J. Pediatr. Orthop.* 10: 754, 1990.
23. Tse, P., Cheng, J., Chow, Y., et al. Surgery for neglected congenital torticollis. *Acta Orthop. Scand.* 58: 270, 1987.
24. Ferkel, R. D., Westin, G. W., Dawson, E. G., et al. Muscular torticollis: A modified surgical approach. *J. Bone Joint Surg. Am.* 65: 894, 1983.
25. Loder, R. T. The Cervical Spine. In R. T. Morrissey and S. L. Weinstein (Eds.), *Lovell and Winter's Pediatric Orthopaedics*. New York: Lippincott-Raven, 1990: Pp. 751-755.
26. Bertrand, C. M. Selective peripheral denervation for spasmodic torticollis: Surgical technique, results, and observations in 260 cases. *Surg. Neurol.* 40: 96, 1993.