

Crouzon syndrome

Ernest L. Bowling, O.D., M.S.,^a and Fernando D. Burstein, M.D.^b

^aPrivate Optometric Practice, Summerville, Georgia; and ^bPediatric Plastic Surgery & Craniofacial Associates, Atlanta, Georgia.

KEYWORDS:

Crouzon syndrome;
Papilledema;
Proptosis;
Craniofacial
syndrome;
Craniosynostosis

Abstract

BACKGROUND: Crouzon syndrome is a rare genetic disorder characterized by distinctive malformations of the skull and facial region. Premature cranial suture closure is the most common skull abnormality. Optic disc edema and proptosis are among the most common ocular findings.

CASE REPORT: We present a case of a 5-year-old girl with Crouzon syndrome displaying classic facial abnormalities along with proptosis and papilledema. The child's condition was improved dramatically after a monoblock advancement procedure.

CONCLUSIONS: The differential diagnosis of the condition and treatment options are discussed. The referring optometrist can play an integral role in the multidisciplinary care the patients require.

Optometry 2006;77:217-222

Crouzon syndrome is a rare genetic disorder that may be evident at birth or during infancy. The disorder is characterized by distinctive malformations of the skull and facial (craniofacial) region. Such abnormalities may vary greatly in range and severity from case to case, including variations among affected family members. However, in most infants with Crouzon syndrome, the fibrous joints between the cranial sutures close prematurely (craniosynostosis). In addition, facial abnormalities typically include proptosis owing to shallow orbits; divergent strabismus or exotropia; ocular hypertelorism; and a small, underdeveloped upper jaw (hypoplastic maxilla), with protrusion of the lower jaw (relative mandibular prognathism). Multiple staged surgeries are the general treatment plan for patients with Crouzon syndrome. With proper treatment, these patients can be productive and active members of mainstream society.

Case report

A 5-year-old girl presented to the office complaining of ocular redness and irritation of a long-standing duration in both eyes (OU). The child's mother stated that the girl "constantly rubs" her eyes and complains of burning. Review of systems was unremarkable; specifically, the mother reported normal labor and delivery as well as normal developmental milestones. There were no anomalies in any siblings or near relatives reported. The child was not on any medications and denied any medical allergies. Her last ocular examination was about 3 years prior, at which time the mother reported, "everything was normal."

Best-corrected visual acuities were 20/30 in the right eye (O.D.) and 20/40 in the left eye (O.S.). External examination found gross proptosis that measured 20 mm on exophthalmometry. The child displayed a flattened bridge and dental malocclusion. The child had incomplete lid closure. Interpupillary distance was 68 mm. Her older brother was present, and had a normal facial appearance, as did the mother and father. Versions were full and smooth without any underactions or overactions of the intraocular muscles. Visual fields were full to finger count confrontation. The child showed gross stereopsis with randot animals. Color

Corresponding author: Ernest L. Bowling, O.D., M.S., 76 Georgia Avenue, Summerville, Georgia 30747.

E-mail: drbowling@alltel.net or ebowling@icare.opt.uab.edu

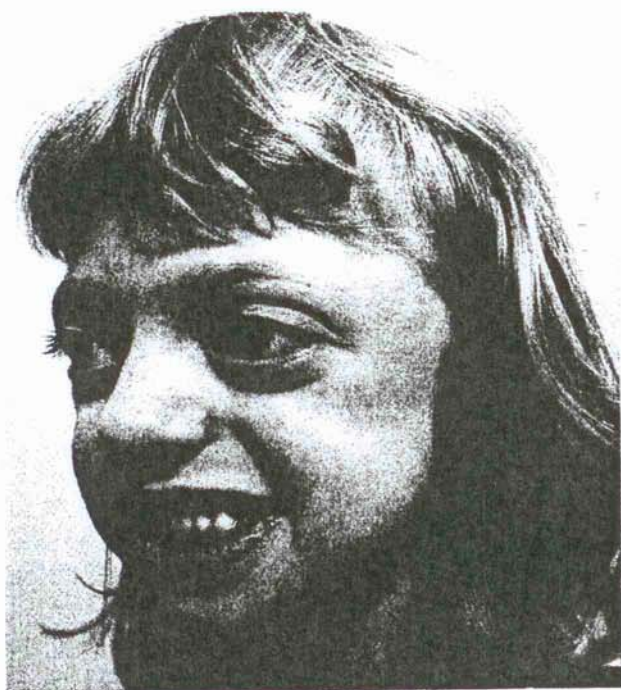

Figure 1 Patient at initial presentation. Note prominent globes.

vision testing was normal in either eye by pseudoisochromatic plates. Pupils were equally round and reactive to light and accommodation without afferent pupillary defect. Slit lamp examination found a moderate interpalpebral conjunctival injection with some small ulcerations on both the nasal and temporal aspects of the bulbar conjunctiva and 360 degrees of diffuse superficial punctate keratitis OU. Intraocular pressures were 15 mmHg OU by Goldmann applanation. Dilated fundus examination found bilateral optic disc edema. Threshold visual fields were attempted, which the child was unable to perform. She was able to complete a 76-point screening field, which displayed some peripheral changes OU (see Figure 1).

The findings were discussed with the child's parents. The child's physical appearance was so strikingly different from other family members, and with the presence of exposure keratopathy and bilateral disc edema, the question was raised if anyone had ever discussed the diagnosis of a craniofacial syndrome.

Treatment of her presenting conditions consisted of non-preserved artificial tears hourly and polytrim ophthalmic ointment. The child was referred immediately to an ophthalmologic consultation center for evaluation of the optic disc edema, where Heidelberg retinal tomography (HRT) was attempted OU, but only O.S. obtained (see Figure 2).

In addition, a referral was made to the Children's Hospital of Atlanta, Center for Craniofacial Disorders for evaluation. There she underwent a battery of tests, including audiology (which was within normal limits), sleep study to evaluate obstructive apnea (a positive test), and genetics evaluation. Medical evaluation found a dysmorphic facies with maxillary hypoplasia, proptosis, and evidence of bicoronal synostosis, all clinical findings consistent with

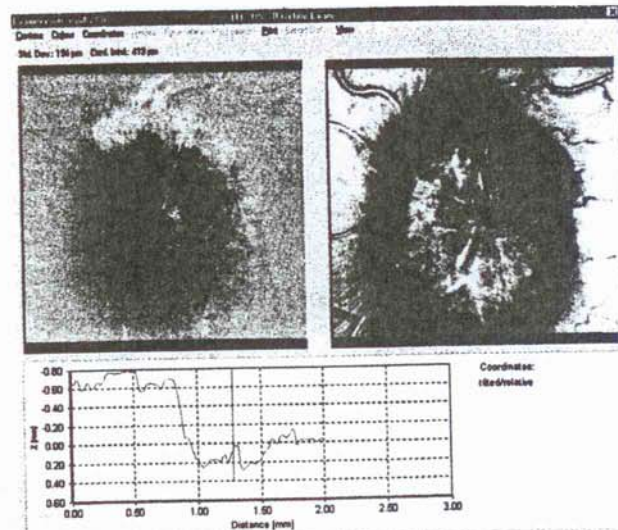


Figure 2 HRT II analysis of patient's left eye. Note optic disc edema.

Crouzon syndrome. Family evaluation found that because "neither parent has any clinical features of (Crouzon), the greatest likelihood is that this represents a de novo mutation." Head computed tomography (CT) scan with 3-dimensional (3D) reconstruction showed bicoronal synostosis and evidence of chronically elevated intracranial pressure. Figure 3 shows the CT scan of the orbits displaying marked proptosis of both globes. Figure 4 shows CT scan of skull displaying premature suture closure.

She underwent combined craniofacial and neurosurgical intervention 2 months after her initial presentation. A monoblock advancement procedure, which opened the closed sutures while advancing the hypoplastic maxilla and orbit was performed using 1-stage resorbable bone distractor. Intraoperative cerebrospinal fluid (CSF) pressure measure-

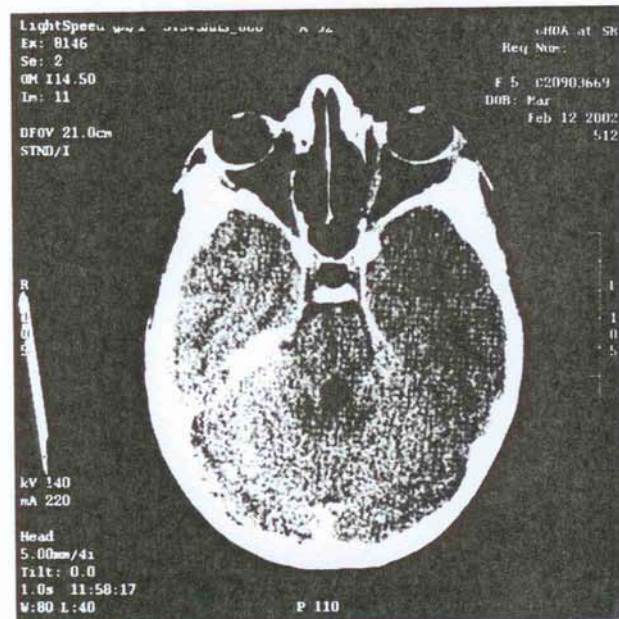


Figure 3 CT scan of orbits show marked proptosis OU.

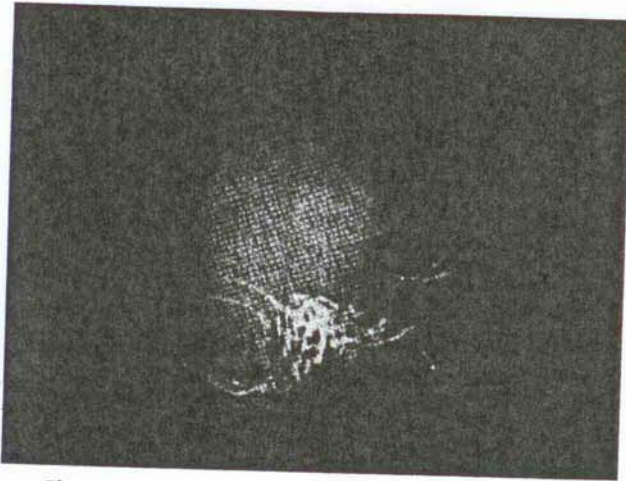


Figure 4 CT scan of skull. Note absence of suture lines.

ments confirmed the radiographic impression of increased intracranial pressure. A total of 20 mm of advancement was achieved, relieving the intracranial pressure and restoring normal facial and orbital morphology as well as occlusion. She tolerated the procedure well and is being followed up by the neurosurgeon at regular intervals. She was returned to the office for followup of the papilledema, which was present but minimal at the 4-month postoperative visit. Visual field defect was no longer present on screening fields. Her uncorrected visual acuity at last visit was 20/20 OU. Figure 5 shows the patient following monoblock expansion advancement surgery.

Discussion

Background

In 1912, Crouzon described the hereditary syndrome of craniofacial dystosis in a mother and son.¹ He described the triad as skull deformities, facial anomalies, and exophthalmos. Premature craniosynostosis, midfacial hypoplasia, and exophthalmos form the triad now known as Crouzon syndrome.² Crouzon syndrome is an autosomal dominant disorder with complete penetrance and variable expressivity.³ It is characterized by premature closure of cranial sutures, most commonly the coronal and sagittal sutures, resulting in abnormal skull growth and affecting growth and development of the orbits and maxillary complex. Other clinical features include hypertelorism, exophthalmos, strabismus, beaked nose, short upper lip, hypoplastic maxilla, and relative mandibular prognathism.⁴ Unlike some other forms of autosomal dominant craniosynostosis, there are no digital abnormalities.⁵ Acanthosis nigricans (a disorder causing velvety, light-brown-to-black markings usually on the neck, under the arms, or in the groin) is the main dermatologic manifestation of Crouzon syndrome.⁶

Characteristics

Crouzon syndrome patients have 3 distinct features⁴:

- Craniosynostosis, most often of the coronal, and occasionally lambdoid or sagittal sutures
- Underdeveloped midface with receded cheekbones or exophthalmos
- Ocular proptosis, which is caused by very shallow orbits. The patient may have strabismus and hypertelorism.

Some other features commonly seen in these patients are visual disturbances related to an imbalance of the extra ocular muscles and hearing loss owing to recurrent ear infections. The mental capacity of Crouzon syndrome patients is usually in the normal range; however, some mental delay has been reported that may be related to increased intracranial pressure.⁷

Pathophysiology

Crouzon syndrome is caused by mutations in the fibroblast growth factor receptor-2 (*FGFR2*) gene, which is mapped to chromosome locus 10q25-10q26.⁸ Fifty percent of incidents of Crouzon syndrome are not inherited and are the result of new mutations.

Premature synostosis of the coronal and sagittal and, in some cases, lambdoid sutures begins in utero and is manifest at birth. The order and rate of suture fusion determine the degree of deformity and disability. Once a suture becomes fused, growth perpendicular to that suture becomes restricted, and the fused bones act as a single bony structure. Compensatory growth occurs at the remaining open sutures to allow continued brain growth, resulting in abnormal bone growth and producing facial deformities. When multiple sutural synostoses occurs, it is likely to initiate to premature



Figure 5 Patient after monoblock expansion advancement surgery.

fusion of the skull base sutures causing midfacial hypoplasia, shallow orbits, a foreshortened nasal dorsum, maxillary hypoplasia, and, in severe cases, upper airway obstruction.

Frequency

Crouzon syndrome occurs in approximately 1 in 25,000 births worldwide.⁹ Prevalence in the United States is 1 per 60,000 (approximately 16.5 per 1,000,000) live births.¹⁰ Crouzon syndrome makes up approximately 4.8% of all cases of craniosynostosis, making it the most common syndrome of the more than 100 within the craniosynostosis group.¹¹ It may be transmitted as an autosomal dominant genetic condition or appear as a mutation.³ No known race or sex predilection exists. The appearance of an infant with Crouzon syndrome can vary in severity from a mild presentation with subtle midface characteristics to severe forms with multiple cranial sutures fused and marked midface and eye problems. Upper airway obstruction can lead to acute respiratory distress.¹² Increased intracranial pressure leading to optic atrophy may occur, which can produce blindness if the condition is not treated.¹³

History

Craniofacial abnormalities are often present at birth and may progress with time. Family history may reveal mildly affected individuals. Decreased mental function is present in approximately 12% of the patients.¹⁴ Headaches and seizures are attributable to elevated intracranial pressure.^{7,15} Visual disturbance can result from corneal damage from exposure secondary to proptosis, as in this case. Conductive loss of hearing is common owing to ear canal stenosis or atresia.¹⁶ Upper airway obstruction develops secondary to septal deviation, midnasal abnormalities, and nasopharyngeal narrowing.¹² Ménière's disease (one of the most common causes of dizziness originating in the inner ear) may develop.¹⁴

Physical findings

Craniosynostosis commonly begins during the first year and usually completes by the second or third year. Coronal and sagittal sutures are most commonly involved, resulting in a high prominent forehead. Ridging of the skull is usually palpable. The most common ocular abnormalities reported are shallow orbits, ocular proptosis, orbital hypertelorism, strabismus, optic atrophy, exposure keratitis, and an unexplained loss of visual acuity.¹⁷⁻²⁰ Unexplained poor visual acuity has been reported as an ocular abnormality in up to 40% of cases.²¹ Shallow orbits are noted on CT scan, and progressive hydrocephalus occurs in 30% of these patients.¹⁴ The exophthalmos (proptosis) secondary to shallow orbits results in frequent exposure conjunctivitis or keratitis and was the presenting condition in this case. There have also been rare occurrences of nystagmus, iris coloboma,

aniridia, anisocoria, microcornea, megalocornea, cataract, ectopia lentis, blue sclera, glaucoma, and luxation of the eye globes.¹⁴ Blindness from optic atrophy secondary to intercranial hypertension can also occur.²² The optic atrophy in Crouzon syndrome cases may be owing to a narrow optic channel.²³ Optic nerve complications were present in 80% of Crouzon patients in one study.⁷

In the mouth, overcrowding of upper teeth, malocclusions, and V-shaped maxillary dental arch have been reported, as has narrow, high, or cleft palate and bifid uvula, along with widely spaced teeth. The ear canals may be narrow or absent, and the middle ear may be deformed.^{14,22} The most common dermatologic manifestation seen in Crouzon syndrome is acanthosis nigricans, which is detectable after infancy. Approximately 5% of patients have the presentation, the hallmark of which is darkened, thickened skin lesions with accentuated markings and a velvety feel.¹⁴

Diagnostic tests—laboratory analysis

More than 50% of patients with Crouzon syndrome have *FGFR2* mutations on molecular analysis. *FGFR2* mutations are also observed in Apert syndrome, Pfeiffer syndrome, and Jackson-Weiss syndrome.²⁴ All patients with associated acanthosis nigricans have the *FGFR3* ala391-to-glu mutation.²⁵

Diagnostic tests—imaging studies

Skull radiographs are used to show synostosis, craniofacial deformities, digital markings of skull, widening of hypophysal fossa, small paranasal sinuses, and maxillary hypoplasia with shallow orbits. The coronal, sagittal, lambdoid, and metopic sutures may be involved. Cervical radiologic abnormalities include butterfly vertebrae and fusions of the bodies and the posterior elements. Cervical fusions are present in approximately 18% of patients. C2-C3 and C5-C6 are affected equally.¹⁴ Comparative CT scan 3D reconstruction analysis of the cranium is used to precisely define the pathologic anatomy and to permit specific operative planning. Magnetic resonance imaging (MRI) is used to show occasional corpus colosum agenesis and optic atrophy.

Differential diagnosis Apert syndrome

Apert syndrome has similar findings to those of Crouzon but with hand and feet malformations.^{2,26} Craniosynostosis combined with symmetric syndactyly of the hands and feet usually involving the second, third, and fourth digits describes Apert syndrome.² Many of the physical deficiencies associated with Apert are present in the Crouzon patient, and both are thought to have similar genetic origins.²⁷ Apert syndrome occurs with an estimated frequency of 1 in 160,000 births.²

Table 1 Craniosynostosis syndromes

Name	Ocular involvement
Crouzon syndrome	Shallow orbits, proptosis, hypertelorism, exotropia Exposure keratitis, globe luxation, optic atrophy
Apert syndrome	Hypertelorism, shallow orbits, strabismus, proptosis, optic atrophy
Pfeiffer syndrome	Hypertelorism, proptosis, strabismus
Carpenter syndrome	Hypertelorism, epicanthal folds, corneal opacities
Saethre-Chotzen syndrome	Hypertelorism, ptosis, strabismus, nasolacrimal duct obstruction, optic atrophy

Modified, from Cohen.¹⁵

Several additional craniosynostosis syndromes also have associated ophthalmic findings, but these syndromes occur much less frequently than Crouzon or Apert syndromes. Nearly all share the craniofacial features common to these 2 most common craniosynostoses, yet they also have certain differences that permit differentiation. These include the syndromes of Pfeiffer, Carpenter, and Saethre-Chotzen.

Pfeiffer syndrome

Pfeiffer syndrome is characterized by craniosynostosis, broad thumbs and great toes, complex cardiovascular malformations, and variable partial soft tissue syndactyly of the hands and feet. The Pfeiffer syndrome has autosomal dominant transmission.

Carpenter syndrome

Signs of Carpenter syndrome include craniosynostosis with craniofacial dysmorphism, finger and toe abnormalities, heart defects, growth retardation, and other disorders. This syndrome has autosomal recessive transmission. Mental retardation is seen in nearly all cases.

Saethre-Chotzen syndrome

Saethre-Chotzen syndrome is a relatively mild form of a congenital bone deformation with a variable pattern of craniofacial, digital, and bone abnormalities. This syndrome is characterized by craniosynostosis, low-set frontal hair line, deviated nasal septum, variable facial asymmetry, and partial cutaneous syndactyly. There is less proptosis and hypertelorism versus Crouzon syndrome.

Table 1 shows the craniosynostosis syndromes and the ocular involvement of each. The true incidence of ocular abnormalities with each of the less common craniosynosto-

sis syndromes has not been determined because of the rarity of reported cases.

Treatment

Treatment by a multidisciplinary team working together with the family provides the best results with any craniofacial disorder. The goal is to stage reconstruction to coincide with facial growth patterns, visceral function, and psychosocial development. In the newborn period, some potential problems that may need to be addressed include respiratory difficulties, feeding problems, neurologic complications such as hydrocephalus, and the potential risk of developmental delay.

Multiple staged surgeries are the general treatment plan for patients with Crouzon syndrome.²⁸ In Crouzon and Apert syndromes, synostosis of 2 or more cranial sutures may be involved, thus producing a risk for increased intracranial pressure and a greater chance of hydrocephalus. Because of the complexity of the surgery, it is common to be prosecuted in stages. In the first year of life, it is preferred to release the synostotic sutures of the skull to allow adequate cranial volume to allow for brain growth and expansion. Skull reshaping may need to be repeated as the child grows to give the best possible results. If necessary, midfacial advancement and jaw surgery can be done to provide adequate orbital volume and reduce the exophthalmus to correct the occlusion to an appropriate functional position and to provide for a more normal appearance. Plastic surgery may also be beneficial. It is one of the few syndromes in which the cosmetic results of the surgery can be strikingly effective, as in our case. Note the difference in facial appearance between Figures 1 and 5.

Prognosis depends on malformation severity. Craniosynostosis can result in brain compression and mental retardation in severely affected individuals unless relieved by early craniectomy. Innovations in craniofacial surgery have enabled patients to achieve their full potential by maximizing their opportunities for intellectual growth, physical competence, and social acceptance. Patients usually have a normal lifespan.

Conclusion

Because of ocular complications such as exposure keratopathy, strabismus, and decreased vision, patients with craniofacial abnormalities may initially present to their primary care optometrist for relief. An understanding of these abnormalities is necessary so the optometrist can make the appropriate referrals to insure the patient receives the best available care. The optometrist can be an integral part of the multidisciplinary care these patients require.

References

1. Crouzon O. Dysostose cranio-faciale hereditaire. *Bull Mem Soc Med Hosp Paris* 1912;33:545-55.
2. Fries PD, Katowitz JA. Congenital craniofacial anomalies of ophthalmic importance. *Surv Ophthalmol* 1990;35(2):87-119.
3. Fogh-Andersen P. Craniofacial dysostosis (Crouzon's disease) as a dominant hereditary affection. *Nord Med* 1943;18:993-6.
4. Dodge HW, Wood MW, Kennedy RLJ. Craniofacial dysostosis: Crouzon's disease. *Pediatrics* 1959;23:98-106.
5. Franceschetti A. Cranial dysostosis with pronounced digital impressions (pseudo-Crouzon dysostosis). In: Beard C. *Congenital Anomalies of the Eye*. St. Louis: C.V. Mosby; 1968:81-4.
6. Gines E, Rodriguez-Pichardo A, Jorquera E. Crouzon disease with acanthosis nigricans and melanocytic nevi. *Pediatr Dermatol* 1996; 13(1):18-21.
7. Bertelson TL. The premature synostosis of the cranial sutures. *Arch Ophthalmol* (Copenhagen) 1958;5(Suppl):47-66.
8. Jabs EW, Li X, Scott AF. Jackson-Weiss and Crouzon syndromes are allelic with mutations in fibroblast growth factor receptor 2. *Nat Genet* 1994;8(3):275-9.
9. Cohen MM Jr. Craniosynostosis update 1987. *Am J Med Genet* 1988;4(Suppl):99-148.
10. Cohen MM Jr, Kreiborg S. Birth prevalence studies of the Crouzon syndrome: comparison of direct and indirect methods. *Clin Genet* 1992;41:12-5.
11. Gray TL, Casey T, Franzco DS, et al. Ophthalmic sequelae of Crouzon syndrome. *Ophthalmology* 2005;112(6):1129-34.
12. Jarund M, Lauritzen C. Craniofacial dysostosis: airway obstruction and craniofacial surgery. *Scand J Plast Reconstr Surg Hand Surg* 1996;30(4):275-9.
13. Pinkerton OD, Pinkerton FI. Hereditary craniofacial dysplasia. *Am J Ophthalmol* 1952;35:500-6.
14. Chen H. *Crouzon syndrome*. eMedicine. Available at www.emedicine.com/PED/topic511.htm. Last accessed March 14, 2004.
15. Cohen MM Jr. An etiologic and nosologic overview of craniosynostosis syndromes. *Birth Defects* 1975;11:137-84.
16. Erneyi S. Craniofacial dysplasia associated with congenital cataracta, impairment of hearing and brachydactyly. *Am J Ophthalmol* 1966;62: 697-702.
17. Reardon W, Von Herwerden L, Rose C, et al. Crouzon Syndrome is not linked to craniosynostosis loci at 7p and 5qter. *J Med Genet* 1994;31:219-21.
18. Perlman JM, Zaidman GW. Bilateral keratoconus in Crouzon's Syndrome. *Cornea* 1994;13:80-1.
19. Posnick JC, Armstrong D, Bite U. Crouzon and Apert Syndromes: Intracranial volume measurements before and after cranio-orbital reshaping in childhood. *Plast Reconstr Surg* 1995;96:539-48.
20. Waitzmann AA, Posnick JC, Armstrong D, et al. Craniofacial skeletal measurements based on computed tomography. Part I. Accuracy and reproducibility. *Cleft Palate-Craniofac J* 1992;29:112-7.
21. Wolter JR. Bilateral keratoconus in Crouzon's Syndrome with unilateral acute hydrops. *J Pediatr Ophthalmol* 1977;14:141-3.
22. Miklaszewska M, Szybejko-Machaj G. *Crouzon syndrome*. eMedicine. Available at www.emedicine.com/derm/topic734.htm. Last accessed March 14, 2004.
23. Basar E, Ercikan C, Korman U, et al. Crouzon Sendromu: oftalmolojik, radyolojik, genetic inceleme. *Turk Oftalmol Gaz* 1992;22: 410-3.
24. Rutland P, Pulleyn LJ, Reardon W. Identical mutations in the FGFR2 gene cause both Pfeiffer and Crouzon syndrome phenotypes. *Nat Genet* 1995;9(2):173-6.
25. Wilkes D, Rutland P, Pulleyn LJ. A recurrent mutation, ala391glu, in the transmembrane region of FGFR3 causes Crouzon syndrome and acanthosis nigricans. *J Med Genet* 1996;33(9):744-8.
26. Jablonski S. Multiple Congenital Anomaly/Mental Retardation (MCA/MR) Syndromes. National Library of Medicine. Available at www.nlm.nih.gov/mesh/jablonski/syndrome_main.html. Last accessed March 24, 2004.
27. Cohen MM Jr. Craniosynostoses: phenotypic/molecular correlation [editorial]. *Am J Med Genet* 1995;56(3):334-9.
28. Posnick JC, Ruiz RL. The craniofacial dysostosis syndromes: current surgical thinking and future directions. *Cleft Palate Craniofac J* 2000;37(5):433.