

Application of the Spanning Plate Concept to Frontal Orbital Advancement: Techniques and Clinical Experience in 60 Patients

Fernando Burstein, MD, Barry Eppley, MD, PhD,* Roger Hudgins, MD,† Joseph Williams, MD, William Boydston, MD, PhD,† Andrew Reisner, MD,† Kevin Stevenson, MD†

Indianapolis, Indiana, USA

Frontal orbital advancement (FOA), is the procedure of choice in treatment of coronal and metopic synostosis. Resorbable plates and screws have been widely accepted for use in pediatric craniofacial surgery, including FOA. We have applied the concept of extended resorbable spanning plates to FOA for metopic, unilateral, and bilateral coronal synostosis in infants and children during a 5-year period. We report on 60 patients, ages 4 to 15 months (mean, 7 months); 28 girls, 32 boys. Follow-up ranged from 12 to 36 months (mean, 24 months). There were no structural failures, no infections, and no complications related to the use of extended spanning plates. Extended spanning plates decrease mobility between bone segments, confer greater stability to the construct, and reduce both the number of plates and of screws that are necessary and reduce the operative time. Application of these plates simplifies FOA surgery and represents a step in the evolution of plating technology.

Key Words: Synostosis, resorbable plates, frontal orbital advancement

The treatment for metopic and coronal synostosis has evolved from simple synostectomy to frontal orbital advancement (FOA), during the last century.^{1,2} Friedenwald, in 1893, recognized that craniosynostosis was associated with optic atrophy and could lead to blindness.³ Lane, in 1892, recognized the association between synostosis and mental impairment.¹ Synostectomy alone does not address the base of cranium or orbital deformities,

and can result in incomplete correction of the orbitocranial deformity.^{4,5} FOA addresses both the suture synostosis and the secondary orbital and cranial deformities. Techniques for FOA have evolved from wire fixation to rigid metallic fixation to resorbable fixation techniques.^{6,7} Wire fixation requires interlocking osteotomy designs, such as the tongue-in-groove technique, for maintaining the advancement during bony healing. These techniques can be technically challenging and time consuming and allowing for the possibility of bony relapse. The application of rigid metallic fixation overcame the osteotomy design limitations and increased stability.^{8,9} Palpable plates and screws, and migration of hardware into an intracranial position through the process of bone resorption and deposition can result when metallic fixation is placed on the growing cranium.⁹ We have previously reported on the safety and efficacy of resorbable fixation systems in craniofacial applications.^{7,10,12} Resorbable plates and screws eliminate many of the problems found with rigid metallic fixation and maintain structural integrity. The spanning plate concept was introduced by McCarthy et al. and first applied to treatment of scaphocephaly.¹³ Recently, Eppley et al. applied the spanning plate concept to a variety of conditions requiring total calvarial reconstruction.¹⁴ These authors used spanning plates to facilitate extensive cranial vault reconstruction and stabilize multiple osteotomy segments. In this study, we extended and modified the spanning plate concept for use in FOA.

MATERIALS AND METHODS

Sixty infants, ages 4 to 15 months (mean, 7 months), were operated on during an 8-year period. There were 28 girls and 32 boys. Three groups of patients underwent FOA, 22 had metopic synostosis, 24 had unilateral coronal synostosis, and 14 had bilateral coronal synostosis. Ten of the patients with bicoronal synostosis also had other associated syndromic findings. All underwent a standard combined

From the *Division of Plastic and Reconstructive Surgery University of Indiana, Indianapolis, Indiana; and †Section of Pediatric Neurosurgery Children's Healthcare of Atlanta, Atlanta, Georgia.

Address correspondence and reprint requests to Fernando D. Burstein MD, FACS, FAAP, Suite 500, 975 Johnson Ferry Road, Atlanta, GA, 30342; E-mail: FBurstein@aol.com

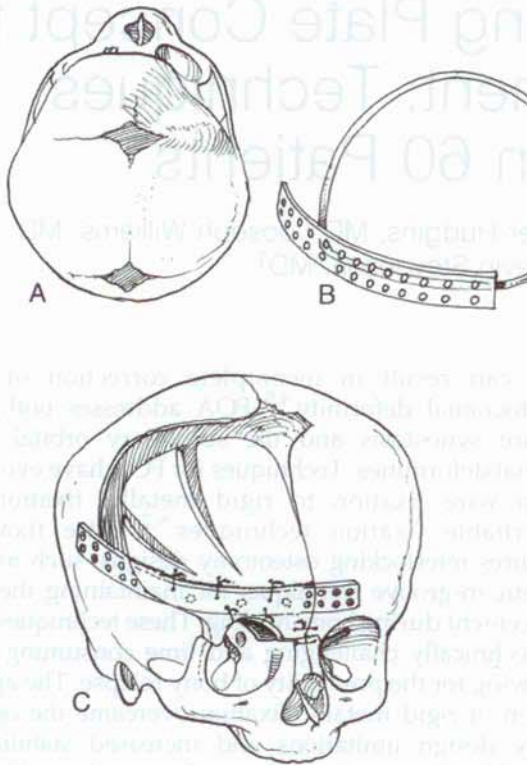


Fig 1 (A) Drawing of a right coronal synostosis. Note the frontal and orbital deformity. (B) Spanning plate that has been heated in a water bath contoured to an age-appropriate template. (C) Final construct with radial osteotomies of frontal bone, which is fixed to frontal orbital bandeau with fine wires for "float". The spanning plate creates the desired radius curve and provides stability.

neurosurgical craniofacial approach to FOA. After removal of the frontal bone and frontal orbital bandeau, osteotomies and bone contouring were used to achieve the desired correction on the back table Figs 1-3. A specially manufactured 240-mm-long, 1-mm-thick plate, with a double row of screw holes was used as a one-piece extended spanning plate for attachment of the frontal orbital bandeau, frontal bone, and bone grafts, as required Figs 1-3. In cases of metopic synostosis, the frontal orbital bandeau was osteotomized centrally and bone grafted as required to achieve the desired frontal width Fig 1. In unilateral coronal synostosis, an overlap of the frontal bone over the frontal bone was used to achieve optimal frontal contour Figs 2, 4. In bilateral coronal synostosis, both sides of the frontal bone were radially osteotomized contoured, and overlapped bilaterally Fig 3. These techniques were varied slightly depending on the severity of the deformity. In all cases, the spanning plate was heated in a thermal water bath and then

contoured to a Marchac template appropriate for the patients age and overall head circumference Fig 2. This contoured spanning plate was then used as the central structural element for attachment of both the frontal orbital bandeau and frontal bone segments. When an overlap technique was necessary, the overlapped frontal bone was attached to the frontal orbital bandeau with either 28-gauge wire or resorbable screws. The entire construct was then returned to the operative field. A 28-gauge wire was passed through the frontal nasal juncture with a wire pass drill bit and the construct was attached via this wire to establish the midline and prevent a bucket-handle effect. With the midline established, the desired advancement at the lateral orbital osteotomy was determined and the spanning plate was attached to the temporal bone with three resorbable screws per side. The lateral canthus was suspended to the spanning plate, and the temporalis muscles were advanced and sutured to the frontal bone to prevent temporal hollowing. The scalp was closed

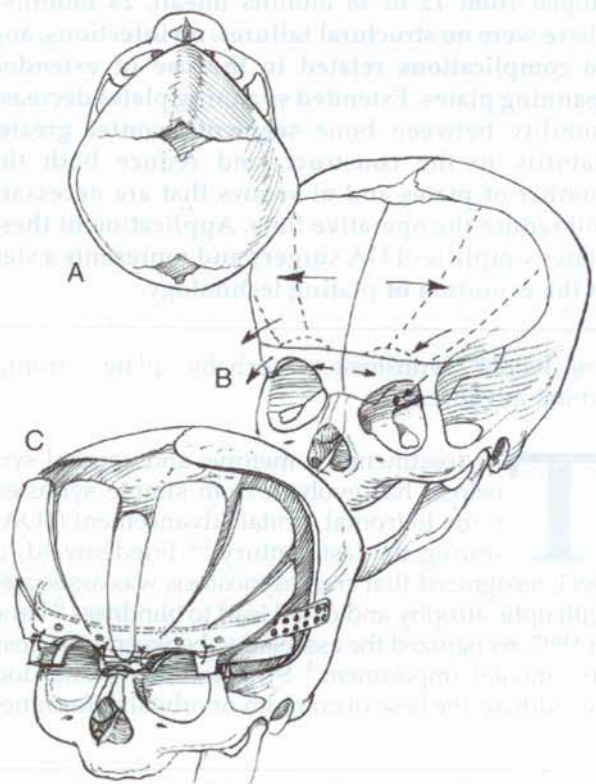


Fig 2 (A) Drawing of metopic synostosis with trigonocephaly. (B) Planned osteotomies with expansion of frontal bone and frontal orbital bandeau. (C) Final construct with overlap of frontal bone, radial osteotomies, and bone grafts for expansion as well as to fill the temporal fossa.

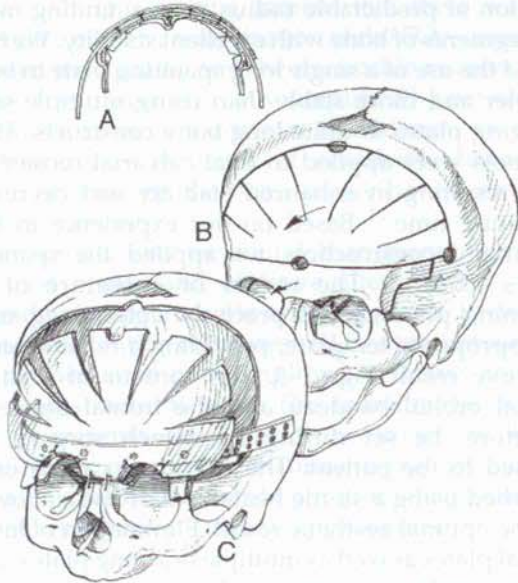


Fig 3 (A) Drawing of bicornal synostosis. Note that the frontal orbital bandeau has been osteotomized and contoured to the spanning plate, and the overlapped frontal bone is wired to the frontal orbital bandeau. (B) Proposed osteotomies and advancement. (C) Final construct. Note the wire between the construct and the nasal bone to prevent rotation.

with resorbable galeal sutures and the scalp stapled. A standard neurosurgical dressing was applied and kept in place for 48 hrs. The patients were discharged after 48 hrs with no medications.

RESULTS

There were no intraoperative or postoperative deaths, infections, or problems requiring immediate reoperation. No bony relapse was observed during the study period, Fig 4. All patients were followed for a minimum of 12 months; range, 12 to 36 months; mean, 24 months. Eight patients (13%) subsequently underwent secondary surgery for temporal augmentation, minor orbital contour deformities, or scalp scar revision.

DISCUSSION

Shillito, in 1968, recognized that strip craniectomy alone would not correct the craniofacial deformities associated with craniosynostosis.⁴ Tessier, Renier, and Marchac demonstrated the safety and efficacy of FOA for the treatment of coronal and metopic synostosis.^{2,6} McCarthy et al. refined these techniques and emphasized the role of the basicra-

nium in synostosis.⁵ Retention of the FOA against tension from the soft-tissue envelope proved to be a challenge. Tongue-and-groove techniques, jumping osteotomies, and bone grafting of osteotomy gaps were combined with wire fixation to prevent bony relapse.^{2,5,6} The design and application of these techniques was technically rigorous and time consuming. In the 1980s, metallic plate and screw fixation was

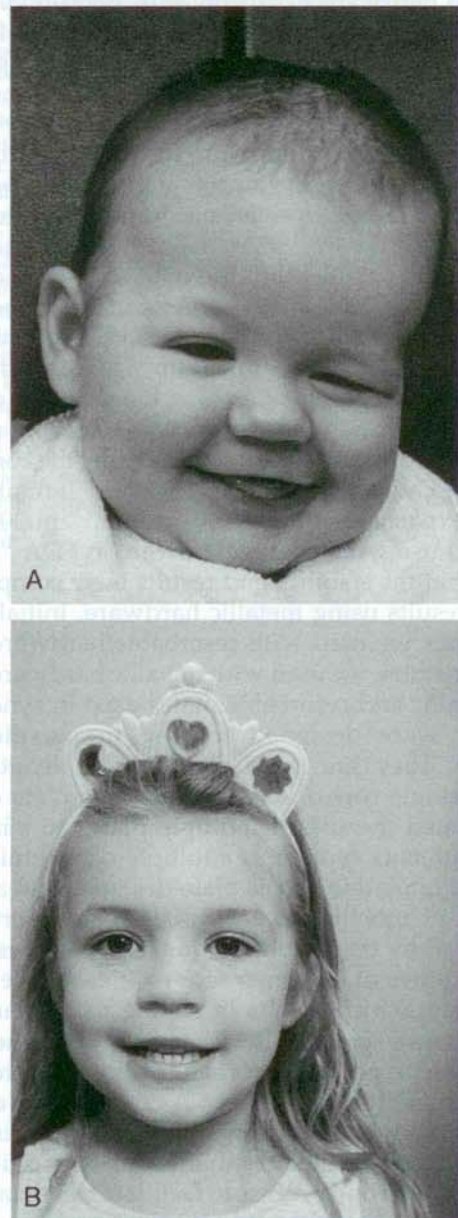

Fig 4 (A) Four-month-old girl with coronal synostosis and resulting frontal and orbital deformities. (B) Patient shown in (A), 3 years after FOA with spanning plate technique.

introduced. Large steel plates and screws gave way to micro-sized hardware made of biologically compatible titanium alloys, which, theoretically, could be left in place indefinitely. These advances allowed for greater freedom of design, and, when properly applied, could increase FOA retention and save operative time. Unfortunately, this new technology was not without problems. The problems included palpable and sometimes painful hardware, and late hardware extrusion with occasional infections. Most worrisome was the finding of what seemed to be hardware migration through the cranium.⁹ The normal process of bone deposition and resorption could carry hardware placed on the outer table of the cranium into the intracranial space. Although usually asymptomatic, we found that several patients experienced headaches centered over the hardware, years later. These headaches resolved after removal of the hardware. Removal of the migrated hardware from its new intracranial location can be a formidable task. These problems have dampened the enthusiasm for using metallic hardware, regardless of size, in the growing craniofacial skeleton. In addition, rigid fixation placed across a suture line, although enhancing the construct stability, could theoretically result in limitation of suture expansion and, hence, growth.^{7,8} In 2001, we reported using resorbable hardware in FOA.^{10,11} We found that the stability and results were comparable to our results using metallic hardware. Initially, the techniques we used with resorbable hardware were similar to those we used with metallic hardware. Both the metallic and resorbable plates used in synostosis surgery were designed for use in maxillofacial surgery. They are relatively short in length and have a single row of screw holes. This plate design necessitated the use of multiple plates to join long bone segments containing multiple osteotomies. An inherent limitation of this plate design is that a small amount of mobility at each plate bone interface is multiplied by the number of individual plates. Each plate requires at least two screws at each side of the osteotomy, which results in having to drill and tap many screws across multiple osteotomies. The manufacturing process for resorbables allows for freedom of design and customization. As our clinical experience grew, we worked with the manufacturer to develop resorbable plates that could be modified in the manufacturing process to facilitate stabilization of multiple bone segments produced in surgical correction of calvarial and frontal orbital deformities. These spanning plates brought the inherent stability of the structural arch to the reconstruction of the cranium.¹⁴ We found that the spanning concept allowed for the

creation of predictable radius curves, uniting multiple segments of bone with excellent stability. We have found the use of a single long spanning plate to be far simpler and more stable than using multiple small bridging plates to unite long bony constructs. These concepts were applied to total calvarial reconstruction, resulting in enhanced stability and decreased operating time.¹⁴ Based on our experience in total calvarial reconstruction, we applied the spanning plates to FOA. The radius of curvature of the spanning plate can be precisely determined using an appropriate template, providing a reliable reconstructive result (Figs 1–3). The contour of both the frontal orbital bandeau and the frontal bone can, therefore, be set during the bench surgery and applied to the patient. The curvature can be easily modified using a sterile heated water bath, allowing for the optimal aesthetic result. Elimination of lateral orbital plates as well as multiple bridging plates saves on the number of screws used and produces a more-stable construct with fewer potential points for material failure. The construct is rigid enough to easily withstand soft-tissue distortion from scalp closure, but to allow the forehead to have a degree of “float”. We know, from previous experience and experimental studies, that the resorbable plate brand we use, LactoSorb (Walter Lorenz Surgical, Jacksonville, FL), loses significant structural strength by 8 weeks after implantation, with the entire construct gradually pivoting on the single trans-frontal nasal wire. This feature allows the brain to slowly push the construct forward, unhindered, as it grows. The spanning plate can safely be applied across suture lines to enhance stability without concern for long-term growth restriction.^{10,11,14} Care should be taken when using resorbable plates in the growing craniofacial skeleton. The resorption characteristics of each manufacturer vary greatly, therefore, we only use the most rapidly and completely resorbable type of polymer marketed under the LactoSorb name. The lack of postoperative hardware complications in our cases decreases both the cost and risk of FOA. Of the patients in this study, 13% underwent secondary orbital reconstruction for minor contour irregularities and scalp scar revision 36 to 72 months after the original surgery. No patients required major revisions for bony relapse or resorption of bone segments. The rate of minor revision is comparable to our overall revision rate before we started using spanning plates for FOA. We found no trace of the spanning plates, or areas of bone resorption under the plates, at the time of revision. We have seen no difference in the rate of secondary reconstruction for minor contour irregularities since we abandoned metallic plates and

screws.^{10,15} This finding implies that there was no difference in the vascularization of the FOA construct between the metallic and the resorbable fixation. The secondary surgery is greatly simplified by not having to remove metallic hardware. In addition, we have not found any evidence of resorbable hardware migration through the bone, as we have seen with metallic implants.¹⁵⁻¹⁷

In conclusion, we found that spanning plates provided a safe and effective alternative to FOA techniques using multiple bridging plates. Establishment and retention of the desired frontal contour was greatly facilitated and simplified by using a single spanning structural plate. The spanning plate concept represents the natural evolution of FOA. Application of current manufacturing technology will allow resorbable hardware to be developed for specific craniofacial surgical applications.

REFERENCES

1. Lane LC. Pioneer craniotomy for relief of mental imbecility due to premature sutural closure and microcephalous. *JAMA* 1892;18:49
2. Marchac D, Renier D. *Craniofacial Surgery for Craniosynostosis*. Boston: Little Brown & Co; 1982
3. Freidenwald W. Cranial deformity and optic nerve atrophy. *Am J Med Sci* 1893;105:529
4. Shillito J, Matson D. Craniostenosis: a review of 519 surgical patients. *Paediatrics* 1968;41:829
5. McCarthy JG. New concepts in the surgical treatment of the craniofacial synostosis syndromes. *Clin Plast Surg* 1979;6:201
6. Marchac D. Radical forehead remodeling for craniosynostosis. *Plast Reconstr Surg* 1978;61:823
7. Eppley B, Sadove M, Havlik R. Resorbable plate fixation in pediatric craniofacial surgery. *Plast Reconstr Surg* 1997;100:1
8. Wiltfang J, Merten H, Becker H, et al. The resorbable mini-plate system Lactosorb in a growing cranioplasty animal model. *J Craniomaxillofac Surg* 1999;27:207
9. Papay F, Hardy S, Morales L, et al. False migration of rigid fixation appliances in pediatric craniofacial surgery. *J Craniofac Surg* 1995;6:309
10. Losken A, Williams J, Burstein F, et al. Outcome analysis for correction of single suture craniosynostosis using resorbable fixation. *J Craniofac Surg* 2001;12:451
11. Eppley B, Morales L, Wood R, et al. Resorbable plate and screw fixation in pediatric craniofacial surgery: clinical experience in 1883 patients. *Plast Reconstr Surg* 2004;15:114
12. Burstein F, Williams J. Resorbable bone distraction: current status and future directions. *Clin Plast Surg* 2004;31:407
13. McCarthy J, Bradley J, Stelnicki E. Hung span method of scaphocephaly reconstruction in patients with elevated intracranial pressure. *Plast Reconstr Surg* 2002;109:2009
14. Eppley B, Li M. Long spanning resorbable plates in cranial vault reconstruction. *J Craniofac Surg* 2003;14:89
15. Goldberg D, Bartlett S, Yu J, et al. Critical review of microfixation in pediatric craniofacial surgery. *Plast Reconstr Surg* 1994;5:110
16. Eppley B, Sadove A. Effects of resorbable fixation on craniofacial skeletal growth: modifications in plate size. *J Craniofac Surg* 1994;5:110
17. Eppley B, Sadove A. Effects of resorbable fixation on craniofacial skeletal growth: a pilot experimental study. *J Craniofac Surg* 1992;4:190