

Applications of Endoscopic Surgery in Pediatric Patients

Fernando D. Burstein, M.D., Steven R. Cohen, M.D., Martin H. S. Huang, M.B., B.S.,
and Cathy A. Sims, R.N.

Atlanta, Ga., and Singapore

Although the advent of endoscopic technology is expanding the fields of reconstructive and aesthetic surgery in adults, there have been few reports of the use of this technology in the pediatric population. Because of their minimally invasive nature, yet wide range of exposure, endoscopic techniques have much appeal for this age group. Here we present our experience with endoscopic pediatric plastic surgery. From February of 1995 to August of 1997, 104 patients underwent 139 procedures utilizing 5- and 10-mm endoscopes. There were 58 male and 46 female patients. The mean age at surgery was 5.6 years (range, 3 weeks to 19 years). The most common type of procedures performed were insertion of tissue expanders ($n = 34$), excision of benign head and neck masses ($n = 27$), torticollis release ($n = 20$), excision of vascular lesions ($n = 13$), and miscellaneous procedures, ($n = 10$). There were 26 complications in 139 procedures (19 percent). Seventeen (65 percent) were in the tissue expander group. The rest were scattered among the groups with other diagnoses. Although there did not appear to be a specific type of complication associated with endoscopy, 77 percent occurred in the first 2 months of our study. This suggests a relatively steep technical learning curve. These results demonstrate that endoscopic techniques are eminently applicable in the pediatric population, providing the benefits of small and remote incisional wounds, with complication rates that are comparable with those of conventional open surgical treatment. (*Plast. Reconstr. Surg.* 102: 1446, 1998.)

Endoscopic surgery was introduced by Jacobaeus in 1910.¹ Improvements in instrumentation, anesthetic techniques, and radiographic imaging have led to a proliferation of surgical endoscopic applications. In the field of otolaryngology, open sinus surgery has been largely replaced by functional endoscopic sinus surgery.² In urologic surgery, orthopedics, neurosurgery, and gastrointestinal surgery, endoscopic procedures are being applied at an ever-

increasing pace, replacing open surgery for many conditions.³⁻⁵ The plastic surgery applications of endoscopic surgical techniques have only recently been recognized.^{6,7} Most of the plastic surgery experience with endoscopic surgery has been for aesthetic applications, in which a premium is placed on the size and location of surgical incisions and on ease of recovery.^{8,9}

In 1994, it became apparent to us that there were many potential uses for endoscopic surgery in the field of pediatric plastic surgery, in which the size and location of the surgical incision are critical. In addition, we believed that, with slight modifications of established aesthetic endoscopic techniques, many common problems seen in the pediatric population could be treated safely and effectively. We were encouraged by our initial experience with 41 pediatric patients and have continued to extend endoscopic applications into pediatric plastic surgery.^{10,11} We report our experience over a 2.5-year period in 104 consecutive pediatric patients on whom we performed endoscopic procedures for a variety of conditions.

MATERIALS AND METHODS

A total of 104 pediatric patients (58 male and 46 female) aged 3 weeks to 19 years (mean 5.6 years) underwent 139 endoscopic surgical procedures between February of 1995 and August of 1997. For purposes of classification, we divided the patients by indications for surgery into six groups—vascular lesions, head lesions, neck lesions, torticollis, tissue expanders, and miscellaneous (Table I). All patients with mid-

From the Center for Craniofacial Disorders at Scottish Rite Children's Medical Center and the Department of Plastic Surgery at Singapore General Hospital. Received for publication November 14, 1997; revised January 29, 1998.

Presented in part at the 65th Annual Meeting of the American Society of Plastic and Reconstructive Surgeons, Dallas, Texas, November 1996.

TABLE I

Summary of Indications for Surgery and Complications in 104 Patients Undergoing Endoscopic Procedures

	No. of Patients	Complications	
		No.	%
Vascular lesions	13	6	46
Head-neck lesions	27	3	11
Torticollis	20	0	0
Miscellaneous	10	0	0
Tissue expanders	34	17	50
Total	104	26	25

Five facial masses underwent a magnetic resonance imaging or computerized axial tomography scan to rule out intracranial extension. Patients with large masses believed to have a vascular origin underwent magnetic resonance imaging scanning to define the depth and extent of the lesion. Instruments and equipment were 5- and 10-mm, 30-degree, down-viewing, rigid endoscopes; xenon light source; microscope-mounted video camera; video monitor and recorder; ergonomic endoscopic scissors and graspers; periosteal dissectors; endoscopic suction cautery; KTP and YAG lasers; and conventional instrumentation as needed. The general principles outlined by Eaves et al.⁶ were used to create an optical cavity and to place incisions for observation and working ports. Dilute lidocaine and epinephrine solution was injected into the anatomic area at least 10 minutes before making any incisions to facilitate dissection and minimize bleeding. Tissue expanders, with buried injection ports, were expanded to 10 percent of their fill volume at the time of placement, and further expansion commenced 1 to 3 weeks later according to the surgeon's preference. The mean period of expansion was 6 weeks (range 4 to 8 weeks). All patients undergoing endoscopic torticollis release had failed physical therapy and had persistent torticollis with facial deformity.

RESULTS

There were 26 operative or perioperative complications noted during the study period (Table I). The majority of complications occurred in the first 3 months of our study (Fig. 1). The greatest number of complications occurred in the tissue expander group. After expander placement, there were three infections, three ruptures, four exposures, three seromas during expansion, and four minor wound dehiscences. All complications that necessitated

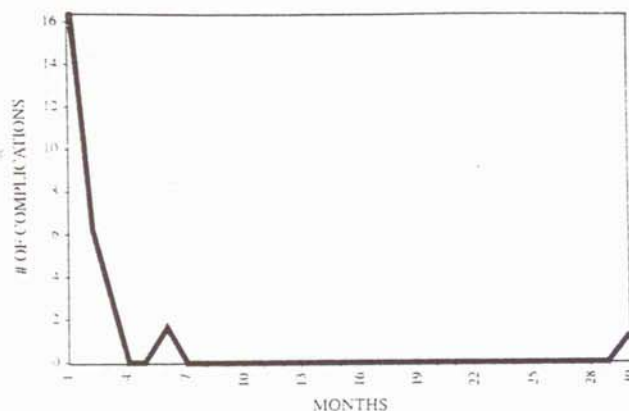


FIG. 1. Graphic representation of the endoscopic complication curve over the period of study. Note that most of the problems occurred early in our experience.

expander removal occurred 3 weeks or more after expander placement. Two of the infected patients responded to oral antibiotics, and expansion was completed, whereas the third did require expander removal. The four exposed expanders necessitated premature removal, at approximately 50 percent of full expansion, providing insufficient tissue for complete reconstruction.

There were three complications in the group of patients with benign head and neck masses. One patient, with a lateral periorbital dermoid cyst, developed a postoperative frontal fluid accumulation with infection, necessitating drainage and antibiotics. Another patient, with a similar lesion, had a postoperative ipsilateral frontal nerve paresis that resolved over a 5-week period. A third patient, with a large dermoid cyst at the nasal glabellar juncture, had necrosis of a 1-cm area of overlying skin caused by thermal damage from a conventional needle-tip cautery. The area healed with minimal scarring with local care only. All other patients in this group healed uneventfully with barely visible incisions and no recurrence of their lesions.

All of the patients who underwent endoscopic torticollis release had complete muscular release without recurrent banding or damage to the spinal accessory nerve. All achieved satisfactory neck range of motion. The incisions in the scalp were virtually invisible in all cases. In the group with vascular lesions, there was one case of incomplete removal that required a secondary open approach; the remaining five complications in this group involved minor skin infections and partial wound dehiscence. Figure 1 gives the temporal rela-

tionship of our complication rates during the study period.

DISCUSSION

The application of surgical endoscopic techniques to pediatric plastic surgery has been made possible by applying techniques used in adult aesthetic and reconstructive surgery.^{6-9,12} In our initial reports, we explored a number of pediatric applications of endoscopic plastic surgery in a limited number of patients.^{10,11} Subsequently, we have refined our indications and techniques, allowing us to broaden the applications. Removal of lesions from the periorbital and frontal areas is performed in much the same way that Ramirez¹³ has reported for forehead and midface lift (Fig. 2). We modified these techniques to account for the size and location of the lesions, but we were able to

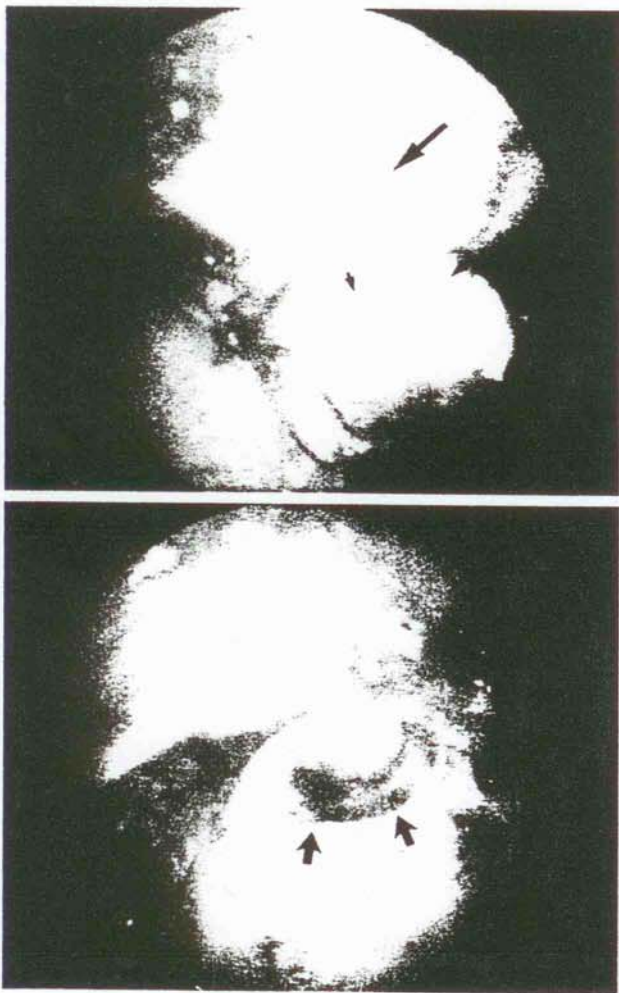


FIG. 2. (Above) Intraoperative endoscopic view of periorbital dermoid cyst (small arrows) and skull (large arrow). (Below) Intraoperative endoscopic view of residual skull defect created by dermoid cyst (arrows).

use similar instrumentation even in very young children. Vascular and lymphatic lesions of the trunk were carried out in a manner very similar to the transaxillary breast augmentation approach reported by Price et al.,¹⁴ with the addition of a small port for the introduction of the laser fiber where needed (Figs. 3 and 4).

The relatively high complication rate, with endoscopic tissue expander placement, is similar to that reported with open techniques.¹⁵⁻¹⁷ Because all of our complications occurred several weeks after surgery, it is difficult to find a single technical cause. Note that our tissue expander complication rate has dropped with increasing experience, which may indicate that the initial problems were at least partly because of inexperience (Table I). There are several advantages to endoscopic expander placement. These include placement of a remote incision distant to the site of expansion so that immediate expansion can be started without fear of wound separation shortening the expansion period. The position of the expander and port can be controlled precisely, because they are visualized directly, avoiding a folded expander or kinked port tubing. Finally, because we visualize the initial expansion in situ, a leaky expander can be recognized at the time of expander placement.

The complications we encountered with removal of benign lesions of the head and neck all occurred early in our series and were caused by technical errors. The temporary frontalis paralysis was caused by traction on the frontal skin flap, which could have been avoided by placing the incision slightly further toward the anterior hairline. The skin loss in the glabellar area was caused by the use of a conventional needle-tip electrocoagulator and insufficient retraction of the overlying skin. This problem subsequently has been avoided by use of a microtip and an electrocoagulator and by placement of a skin hook or traction suture into the overlying skin to ensure adequate skin clearance. Although small orbital dermoid cysts usually can be resected through a lid-fold incision, leaving an inconspicuous incision, this approach may be difficult when there is tight periosteal attachment. The traction that needs to be exerted to gain adequate exposure, and the splitting of the orbicularis muscle fibers may lead to prolonged lid edema and have the potential of damaging the delicate levator mechanism of the infant eyelid. In larger lateral orbital dermoid cysts that extend into the

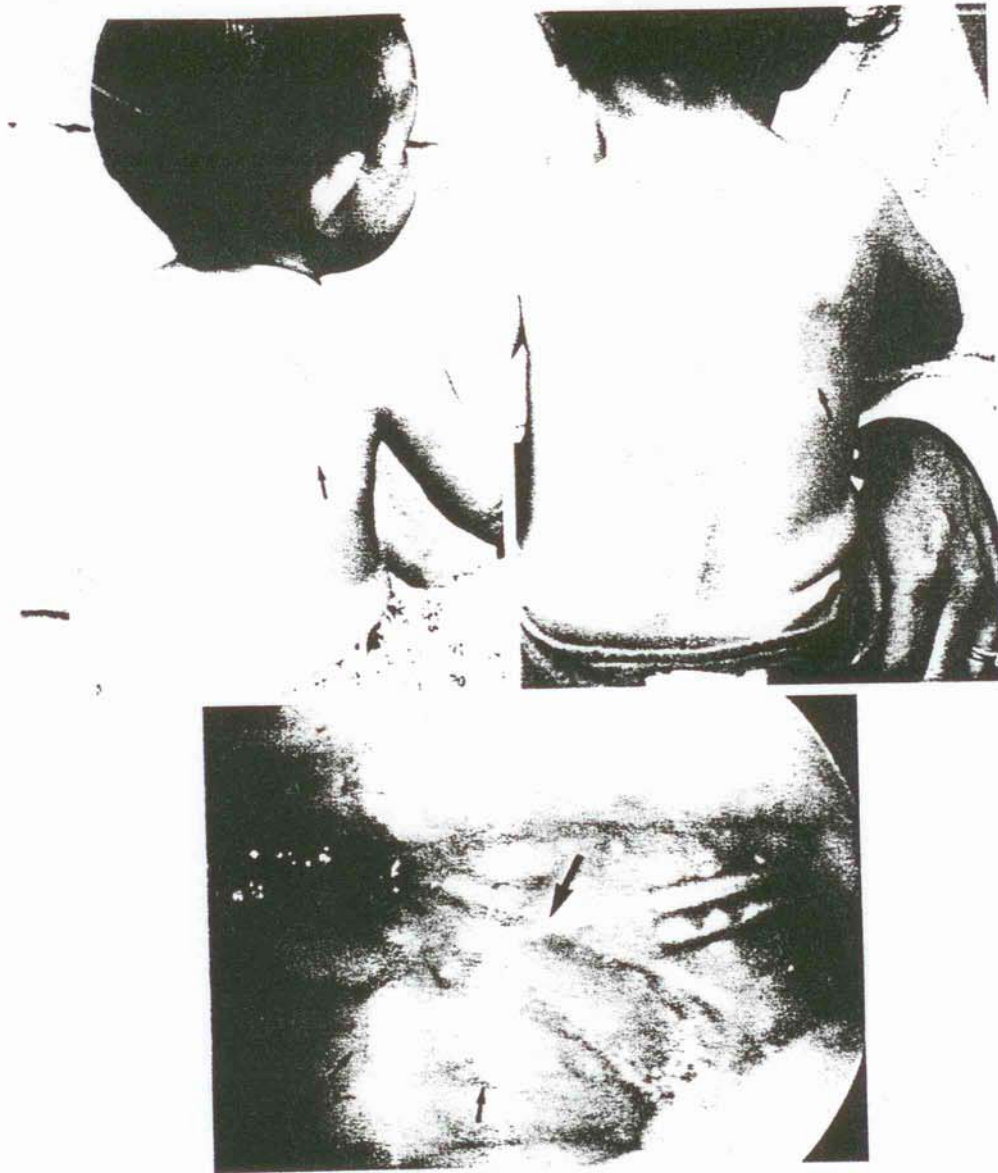

FIG. 3. (Above, left) Large growing suprascapular vascular mass (arrow) in a 2-year-old girl. (Below) Intraoperative endoscopic view of Nd-Yag laser fiber (large arrow) introduced through an axillary port incision used to excise lesion shown in above, left (small arrows). (Above, right) Nine-month postoperative follow-up. Note absence of residual defect or external scar. Area of previous lesion is shown by arrow.

temporal fossa, a coronal incision, with the attendant risk of frontal nerve damage and alopecia, may be necessary in addition to the translid approach to achieve complete removal. The endoscopic approach combines submuscular and subperiosteal dissection with magnification, allowing for precise removal without splitting the orbicularis muscle or turning a coronal flap. In addition, magnification allows for precise dissection, avoiding spillage of the cyst contents. Even large orbital dermoid cysts can be removed through a combination of frontal and temporal port incisions. There

were no cases of alopecia or conspicuous scarring (Fig. 2).

We followed generally accepted indications for surgical management of lymphatic and vascular lesions.¹⁸ These included interference with vision, eating, breathing, limb function, persistent rapid growth, and psychological distress to the parents secondary to deformity caused by the lesion. Vascular lesions were approached initially by using sharp dissection and conventional cautery, but difficulties in predicting the exact zone of thermal damage and smoke evacuation have led us to the use of

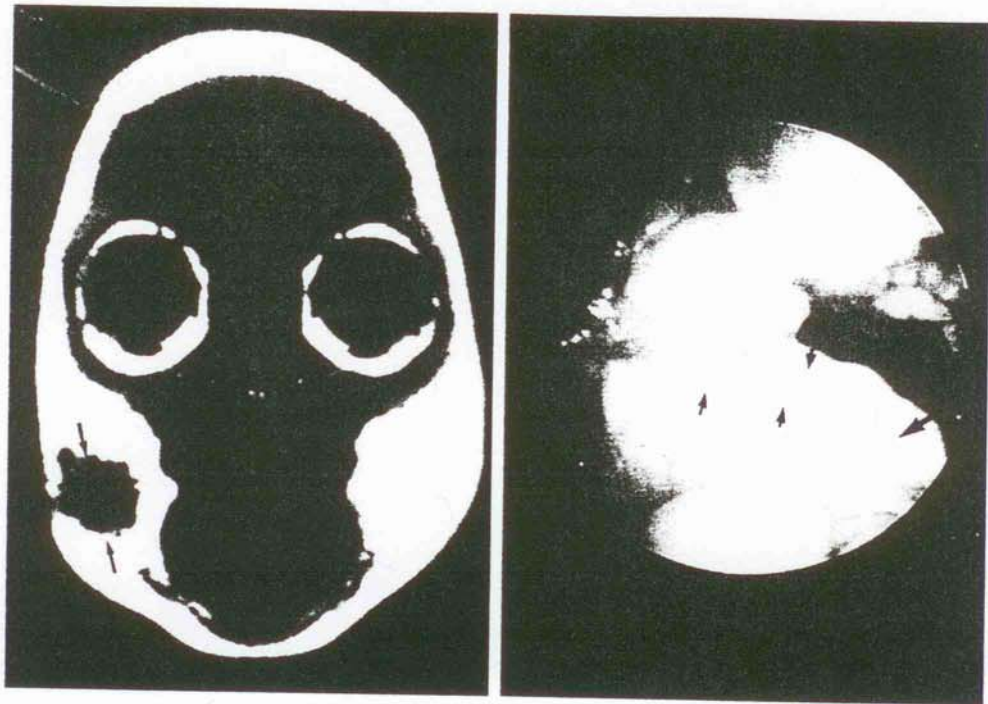


FIG. 4. (Left) Magnetic resonance imaging scan of infant with large lymphatic malformation in soft tissues of the face (arrows). (Right) Intraoperative endoscopic view of lymphatic malformation of face (large arrow). Facial nerve branches (small arrows) are visualized and protected.

the YAG and KTP lasers, which have found wide acceptance in other endoscopic applications.¹⁷⁻²¹ The laser light can be transmitted through a thin, fiberoptic fiber coupled to a smoke evacuating handpiece, which is introduced through a small working port. The use of large amounts of local anesthetic with epinephrine in a "wet" type of technique afforded excellent hemostasis and aided with skin flap elevation. The larger feeding vessels were visualized easily with the magnification afforded by the endoscope and laser coagulated. None of these patients needed to be transfused. The only unsatisfactory result was in a patient with extensive deep dermal involvement in whom incomplete endoscopic removal led to recurrence and need for open reoperation. The endoscopic technique is ideal for vascular lesions or lymphatic malformations that have relatively normal overlying skin (Figs. 3 and 4). In cases with superficial and subcutaneous involvement, we have combined endoscopic debulking of the deep component with tunable dye laser treatment of the cutaneous component.

We recently reported our technique and indications for endoscopic release of torticollis in infants with one or two small scalp ports.¹¹ This technique evolved from our dissatisfaction with

the scarring left by conventional open techniques. To date, we have achieved complete muscular release without recurrent or persistent bands and with no instances of damage to the spinal accessory nerve. The direct visualization of neurovascular structures with magnification has allowed us to maintain the innervation to both the distal and proximal sternocleidomastoid muscles, preserving functional muscle mass with complete muscular release. The scars left by the port incisions have been nearly invisible.

The application of surgical endoscopy to problems in pediatric plastic surgery has significant drawbacks. These include the cost of equipment, the lack of training courses for these specific indications, and the relatively long learning curve we experienced (Fig. 1). We agree with Howard et al.²² that the complications associated with endoscopic techniques are similar to those with open techniques. In addition, at least initially, the operating times will be longer than with comparable open techniques. We have found that our operating times have decreased markedly with experience and are now comparable with our open operating times. Specific pediatric endoscopic instrumentation is not yet available, so adult instruments have to be adapted to the shorter

working distances. Despite these limitations, we see an expanding role and more indications for endoscopic applications in the pediatric age group. The visualization and magnification afforded by the endoscope make identification and preservation of important anatomic structures easier and dissection of lesions more precise. Coupling of endoscopic techniques with a variety of fiberoptic lasers will open new avenues of treatment for vascular and lymphatic malformations with decreased scarring.

Fernando D. Burstein, M.D.
The Center for Craniofacial Disorders
5455 Meridian Mark Road, Suite 200
Atlanta, Ga. 30342

REFERENCES

- Jacobaeus, H. C. Zystoskopie. *Munch. Med. Wochenschr.* 40: 2090, 1910.
- Maran, A. G. Endoscopic sinus surgery. *Eur. Arch. Otorhinolaryngol.* 251: 309, 1994.
- Tolley, D. A. Primary endoscopic surgery for ureteric stones. *Br. J. Urol.* 64: 130, 1989.
- Caputy, A., Starr, J., and Riedel, C. Video-assisted endoscopic spinal surgery: Thoracoscopic discectomy. *Acta Neurochir. (Wien)* 134: 196, 1995.
- Cairns, S. R., Dias, L., Cotton P. B., Salmon, P. R., and Russell, R. C. Additional endoscopic procedures instead of urgent surgery for retained common bile duct stones. *Gut* 30: 535, 1989.
- Eaves, F. F., III, Price, C. I., Bostwick, J., III, et al. Subcutaneous endoscopic plastic surgery using a retractor mounted endoscopic system. *Perspect. Plast. Surg.* 7: 1, 1993.
- Eaves, F. F., III, Bostwick, J., III, and Nahai, F. Instrumentation and setup for endoscopic plastic surgery. *Clin. Plast. Surg.* 22: 591, 1995.
- Ramirez, O. M. Endoscopic full facelift. *Aesthetic Plast. Surg.* 18: 363, 1994.
- Johnson, G. W., and Christ, J. E. The endoscopic breast augmentation: The transumbilical insertion of saline-filled breast implants. *Plast. Reconstr. Surg.* 92: 801, 1993.
- Huang, M. H. S., Cohen, S. R., Burstein F. D., and Simms, C. A. Endoscopic pediatric plastic surgery. *Ann. Plast. Surg.* 38: 1, 1997.
- Burstein, F. D., and Cohen, S. R. Endoscopic surgical treatment for congenital muscular torticollis. *Plast. Reconstr. Surg.* 101: 20, 1998.
- Miller, M. J. Minimally invasive technique of tissue harvest in head and neck reconstruction. *Clin. Plast. Surg.* 21: 149, 1994.
- Ramirez, O. M. Endoscopic techniques in facial rejuvenation. An overview: Part I. *Aesthetic Plast. Surg.* 18: 141, 1994.
- Price, C. I., Eaves, F. F., III, Nahai, F., Jones, G., and Bostwick, J., III. Endoscopic transaxillary subpectoral breast augmentation. *Plast. Reconstr. Surg.* 94: 612, 1994.
- Neale, H. W., High, R. M., Billmire, D. A., Carey, J. P., Smith, D., and Warden, G. Complications of controlled tissue expansion in the pediatric burn patient. *Plast. Reconstr. Surg.* 82: 840, 1988.
- Austad, E. D. Complications in tissue expansion. *Clin. Plast. Surg.* 14: 549, 1987.
- Marks, M. W., Argenta, L. C., and Thornton, J. W. Burn management: The role of tissue expansion. *Clin. Plast. Surg.* 14: 543, 1987.
- Burns, A. J. Vascular anomalies, lasers and lymphedemas (overview). *Select. Read. Plast. Surg.* 7: 1, 1992.
- Hunter, J. G. Advantages of laser application in endoscopic surgery. *Endosc. Surg. Allied Technol.* 1: 213, 1993.
- Oho, K., Ogawa, I., Amemiya, R., et al. Indications for endoscopic Nd-Yag laser surgery in the trachea and bronchus. *Endoscopy* 15: 302, 1983.
- Hunter, J. G., Bowers, J. H., Burt, R. W., Sullivan, J. J., Steven, S. L., and Dixon, J. A. Lasers in endoscopic gastrointestinal surgery. *Am. J. Surg.* 148: 736, 1984.
- Howard, P. S., Gardner, P. M., Vasconez, L. O., and Core, G. B. Complications in endoscopic plastic surgery. *Clin. Plast. Surg.* 22: 791, 1995.