

Primary Aesthetic Rhinoplasty in Adolescents: Indications and Techniques

Fernando D. Burstein



esthetic rhinoplasty in adolescents has become an increasingly accepted and sought-after procedure.^{1,2} Appropriate timing and patient selections are essential for a successful outcome. Adolescence is a critical period for psychological and physiologic development. It represents a crucial period in the formation of self-image and self-esteem. Peer pressure, parental expectations, and media images all play a role in the development of the self-image.^{3,4}

INDICATIONS AND CONTRAINDICATIONS

The patient's psychological maturity, expectations of the patient and parents, and aesthetic and functional requirements must be considered before surgery.⁵ The patient should be physically mature or nearly physically mature. Boys should have begun shaving, girls should have started menstruating, and both should be nearly as tall as adults. If there is a question of maturation and growth potential, a hand-wrist radiograph can be used to compare bone age with chronologic age. Akgüner et al⁶ reported that adult nasal proportions and growth are reached by 13 years of age in females and 15 years of age in males. Ortiz-Monestario and Olmedo⁷ reported satisfactory long-term growth and aesthetic results with early rhinoplasty. Preoperative consultation should include a psychological assessment and physical examination.^{7,8} A history of psychiatric illness or unrealistic expectations on the part of the patient or parents is a relative contraindication to surgery.⁹ Parents and their child should express similar expectations and aesthetic goals during their initial interviews. Patients who arrive for their first consultation with a collection of photos from popular magazines demonstrating their ideal nasal shape and size may not have realistic goals.⁸

Box 34-1 Key Steps of the Preoperative Assessment

- Select appropriate candidates.
- Confirm that the parents' and the patient's expectations are the same.
- Be cautious with patients and parents who have unrealistic expectations.
- Ask about current or historical treatment for emotional or psychiatric issues.
- Provide photographic documentation.
- Perform an external and intranasal exam.
- Perform adjuvant endoscopic and radiographic examinations.
- Provide patient education and obtain written consent.
- Assess all surgical anatomy.

PREOPERATIVE ASSESSMENT

The ideal nose varies by sex, ethnicity, and individual aesthetic preference.^{9,10} The patient may want to preserve certain familial or ethnic nasal traits, even though doing so may compromise what I consider to be an optimal aesthetic result. I evaluate several anatomic areas when examining the external nasal features including the radix, dorsum, supratip, tip, columella, and alae. In addition, the nasofrontal, tip-columellar, and nasolabial angles are measured.^{10,11} Skin character and thickness are noted. Patients with active acne are not candidates for rhinoplasty. Patients who have been treated with Acutane require a full year after discontinuing the medication for regeneration of pilosebaceous appendages and normal healing. Generally accepted measurements of facial proportions can be applied in documenting the patient's particular aesthetic deformity.^{10,11} Standard photographic documentation includes frontal, oblique, lateral, and worm's-eye views of the face.¹² If an underlying bony facial disproportion is suspected, a lateral cephalometric radiograph can be very helpful in defining the problem when considering adjunctive bony surgery.^{12,13} I have found that computerized imaging can be a valuable communication tool that allows the patient and surgeon to share a visual image of the desired changes and the potential outcome of surgery.¹⁴ I require written consent if imaging is done, noting that imaging is an artistic representation used for patient communication purposes and does not imply a guarantee of results.⁸ The physical and medical histories should include any history of allergies, nasal medications, trauma, and previous nasal surgery. A history of constant, not seasonally related, nasal airway obstruction suggests that there is an accompanying internal nasal deformity. An intranasal speculum examination and Q-Tip test of nasal valve patency are useful.¹⁵ In some patients with a history of significant airway obstruction, nasometry and flexible endoscopy can be added to the preoperative evaluation. If a significant functional airway component exists, it is addressed at the time of aesthetic rhinoplasty.

Before surgery, information sheets covering all aspects of the preoperative routine and postoperative care are given to the patient. The informed consent process includes an extensive written consent as well as a verbal informed consent covering potential complications, the expected time course for healing, and reasons to call me during the postoperative period, such as high fevers. A duplicate copy of the consent form is given to the patient; records of this process are kept in the patient's chart. Key aspects of the preoperative assessment are listed in *Box 34-1*.

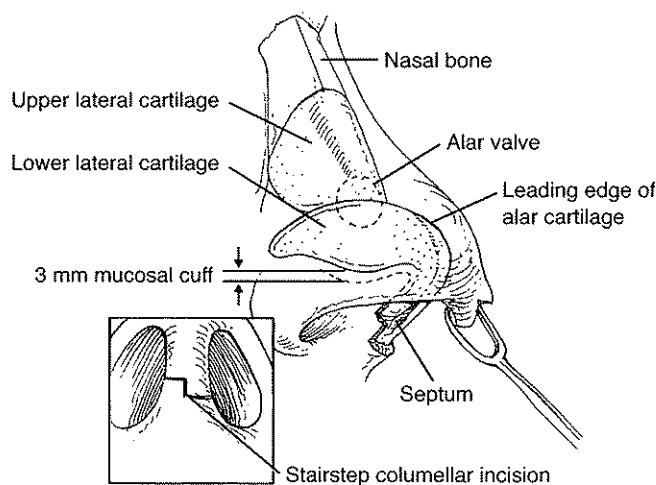


Fig. 34-1 Surgical anatomy and stairstep incision (*insert*). Note the preservation of the mucosal cuff and the location of the physiologic alar valve.

SURGICAL ANATOMY AND PHYSIOLOGY

Pertinent surgical anatomy of the nose includes the paired nasal bones, upper and lower lateral cartilages, nasal spine, and septum^{10,11,16-18} (**Fig. 34-1**). Critical physiologic functions of the nose include air filtration and humidification.¹⁵ Key areas that determine nasal laminar airflow include the piriform aperture, alar inlet, and alar valve, which is located at the juncture of the upper and lower lateral cartilages with the nasal septum.¹⁸ Nasal airflow can be negatively affected by mucosal scarring, weakening of the nasal valve, or failure to address turbinate hypertrophy.¹⁹

OPERATIVE TECHNIQUE

Basic Technique for Reductive Rhinoplasty

General anesthesia is recommended along with a 0.25% mepivacaine field block and 4% cocaine of the mucosa to keep bleeding to a minimum and postoperative comfort to a maximum (**Fig. 34-2**). I prefer to anesthetize the nose at least 10 minutes before starting the procedure. The cocaine pledgets are placed between the lower and middle turbinates to produce a profound block of the sphenopalatine ganglia. Mepivacaine is injected into the septal mucosa, elevating the mucoperichondrium; subcutaneously along the dorsum and tip; and as a field block of the infraorbital, supratrochlear, and supraorbital nerves. Vibrissae are trimmed and removed. These maneuvers ensure that the patient is comfortable for the first 18 to 24 postoperative hours. Intraoperative antibiotic agents are given along with steroids.

I prefer an open approach to rhinoplasty.²⁰ This exposure allows visualization of the entire nasal anatomy and, if necessary, easy access to the septum and internal nasal valve. Full exposure of the pertinent anatomy allows precision with every maneuver, largely eliminating late shifting of structures or graft displacement, and increasing the predictability of the procedure. The fully displayed anatomy is also helpful for surgical assistants and when teaching residents. A systematic, stepwise approach to rhinoplasty is followed, which addresses all aesthetic and functional

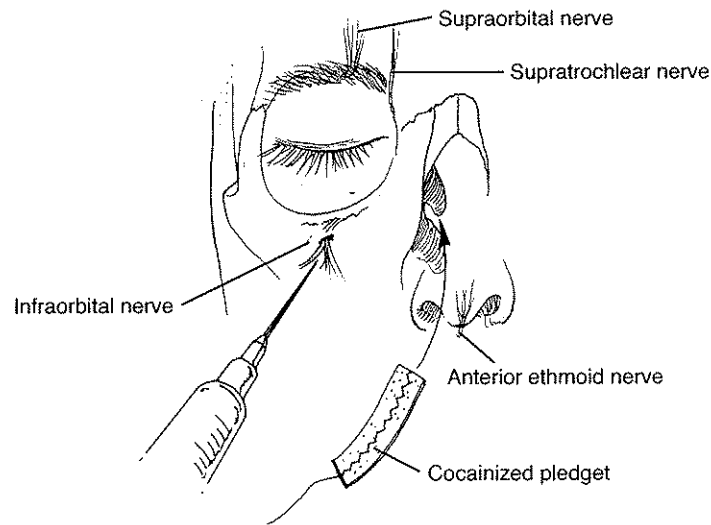


Fig. 34-2 The location of mepivacaine field blocks are shown including the anterior ethmoidal, infraorbital, supraorbital, and supratrochlear nerves. Cocainized pledgets for mucosal vasoconstriction are placed between the lower and middle turbinates.

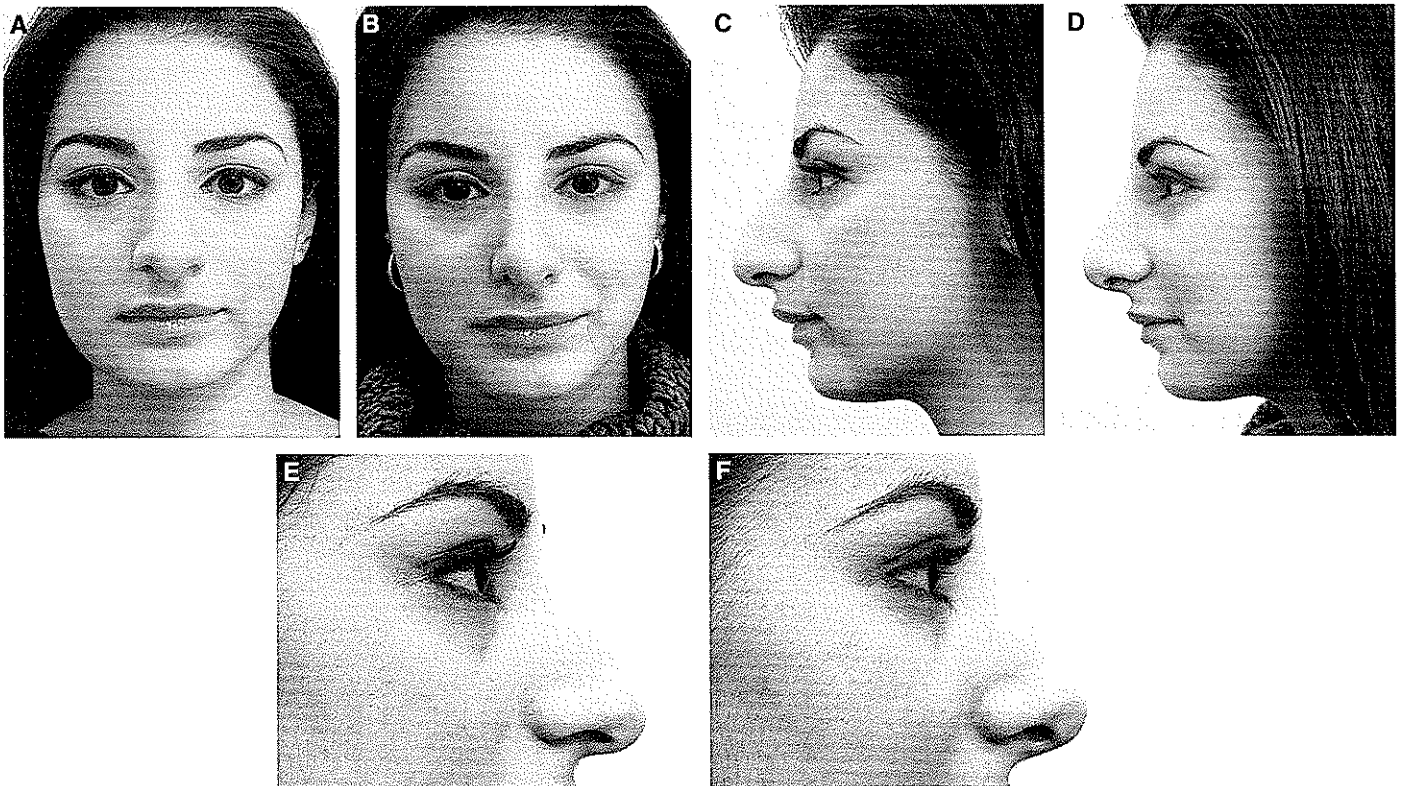


Fig. 34-3 A-F, This 17-year-old patient requested a reduction of her nasal dorsum and a decrease in the overall projection without compromising her ethnicity. Conservative reduction of the bony as well as cartilaginous dorsum was performed with lateral osteotomies. The lower lateral cartilages were reduced with dome sutures to decrease the width.

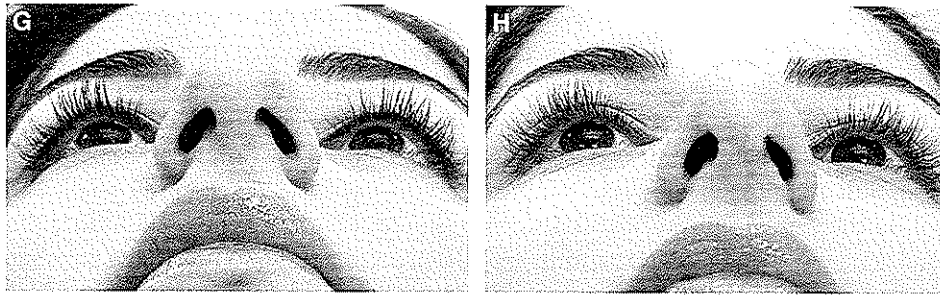


Fig. 34-3, cont'd G and H, Preoperative and postoperative submental vertex views. The stair-step incision has healed well at 9 months.

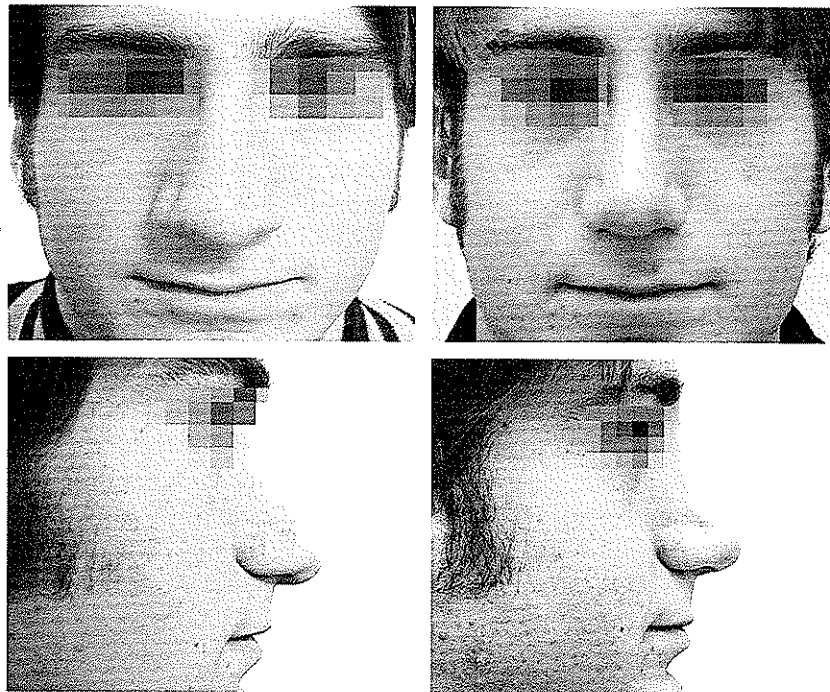

Fig. 34-4 This 16-year-old patient had a broad, amorphous nose; thick, sebaceous skin; and an acute nasolabial angle. He underwent dorsal reduction, lateral osteotomies, and reduction of his lower lateral cartilages with bruising of the lateral crura to reduce the width. Bilateral alar spreader grafts were used to define aesthetic lines of the dorsum. Columellar graft was used to support the tip, and shield graft was added for tip definition.

needs of the patient^{20,21} (*Figs. 34-3* and *34-4*). This method allows maximum flexibility and creativity, prevents the duplication of surgical steps, and minimizing operative time.²²⁻²⁴ A stair-step incision in the midcolumella is preferred (see *Fig. 34-1*). The right angles allow easy alignment and closure. This pattern has proved to result in a very well camouflaged, barely visible incision with a scar revision rate of less than 1%. Care is taken to accurately find the leading edge of the lower lateral cartilages. This is facilitated by using a thumb hook and digital pressure to evert the lower lateral cartilages as sharp scissor dissection proceeds. Careful dissec-

tion is necessary to prevent damage to the delicate inferior edge of the cartilage and to preserve the delicate vestibular skin, particularly at the soft triangle. I recommend leaving a 3 mm rim of intact mucosa even if it requires retrodissection of the alar cartilages (see Fig. 34-1).

Once the lower lateral cartilages have been dissected, the dorsum is dissected with Ragnell scissors to expose the upper lateral cartilages and nasal bones (*Fig. 34-5, A*). The skin thickness is kept uniform as it is elevated. If cartilage grafts are required or if there is a functional component, the septum is approached by retracting the footplates of the lower lateral cartilages and cutting down on the caudal septum with needle-tip cautery (*Fig. 34-5, B*). A 1 cm strip of caudal septum and a 1.5 cm strip of dorsal septum are left intact during septal cartilage harvesting. Failure to leave adequate dorsal septum can result in a saddlenose deformity. If the caudal septum is badly deviated it can be resected at this time, and a columellar graft can be used to provide stability.^{20,21} If there is a significant deviation of the nasal spine, it is corrected, which usually involves a reduction with small rongeurs. Any bony or cartilaginous septal deviation or turbinate hypertrophy is addressed. The septal mucoperichondrial flaps are sutured to each other with resorbable mattress sutures to prevent a septal hematoma, thus avoiding nasal packing (*Fig. 34-5, C*). The bony dorsum is addressed next. A combination of coarse to fine rasps is used to achieve the desired nasal bony contour (*Fig. 34-5, D*). Junction tunnels between the upper lateral cartilages and septum are dissected at this time, preserving the mucosa. If spreader grafts are necessary, they are placed into these junction tunnels later in the procedure. The excess cartilaginous septum is reduced 1 mm at a time with a combination of a No. 11 scalpel and cartilage scissors until the desired nasal profile is achieved (*Fig. 34-5, E and F*). The skin envelope is reapplied after each reductive step, and the nasal dorsum is visually inspected as well as palpated for any irregularities.²⁴⁻²⁶ Having the patient's imaging study, especially the profile, available allows precise contouring of the dorsum.^{22,24} Care is taken to preserve the upper lateral cartilages and their attachments to the nasal bones, lower lateral cartilages, and septum, as well as all mucosa. Reduction of the bony and cartilaginous nasal dorsum results in an open nasal roof of varying degrees, depending on the amount of dorsal reduction. This is addressed by performing a low-to-high osteotomy with a 2 mm osteotome inserted at the piriform aperture level (*Fig. 34-5, G*). The inferior-most aspect of the piriform rim is palpated with the tip of the osteotome, and the osteotomy proceeds with the osteotome parallel to the maxilla until the medial canthal level is reached. The osteotome is then turned 90 degrees to complete the osteotomy across the nasal bones (see Fig. 34-5, G). No subperiosteal tunneling is necessary because the periosteal bridges enhance the stability of the osteotomies. Gentle digital pressure completes the osteotomy, mobilizing the nasal bones medially and closing the open roof. This technique produces a very stable and reproducible low-to-high greenstick-type osteotomy. The advantages of the external osteotomy, which include stability, reduced edema, better control of the fracture line, and less mucosal damage, are preserved without an external incision.²⁵ The dorsum is visually inspected and palpated for irregularities, which can be rasped. The middle vault is visually inspected.²⁶ The upper lateral cartilages can be conservatively trimmed if they are protruding above the septal plane (see Fig. 34-5, E). Any excess in the lower cartilages is addressed (see Fig. 34-5, G). The cephalic rim is trimmed using a No. 15 scalpel and sharp scissors. At least 4 mm of alar rim cartilage should be preserved to maintain the integrity of the nasal inlet (*Fig. 34-5, H*). Complete transaction of the lower lateral cartilages is avoided to prevent pinching of the tip and airway compromise from alar rim collapse.^{15,18} The medial crura and footplates are sutured together, with absorbable PDS to achieve the desired nasal width and tip projection (*Fig. 34-5, I*).

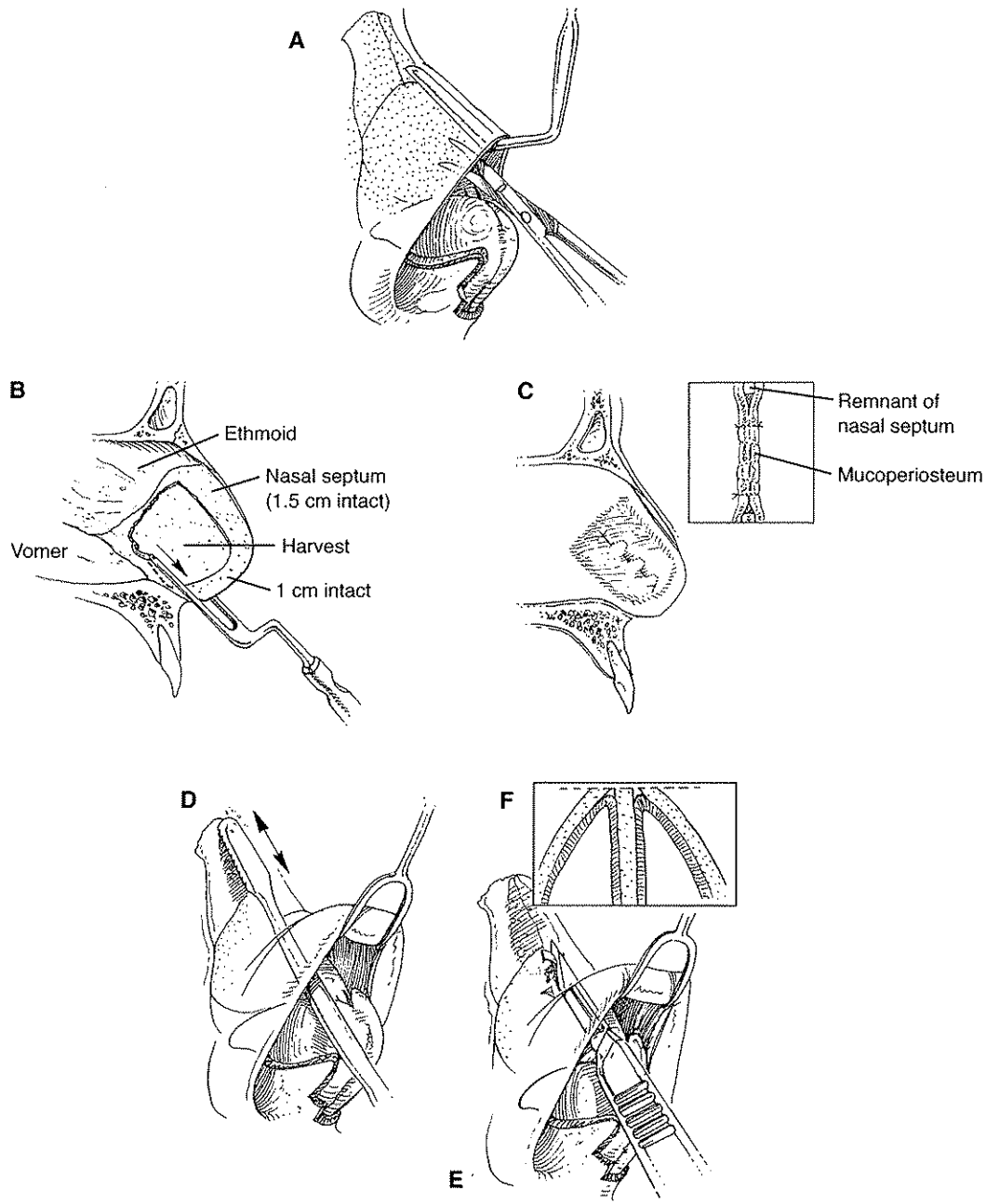


Fig. 34-5 **A**, A skin envelope is raised with uniform thickness, preserving cartilage. Lateral attachments to the nasal bone are minimally undermined to maintain stability. **B**, The central septum is harvested with a swivel knife. The dorsal strut is preserved to prevent a saddlenose deformity. The caudal strut is preserved for tip support. **C**, To avoid nasal packing and prevent a septal hematoma, the mucoperichondrial flaps of the septum are reapproximated using resorbable mattress sutures. **D**, Coarse to fine rasps are used to achieve the desired dorsal bony contour. **E**, After the dorsal bony contour has been set, the cartilaginous dorsum is slowly contoured with a No. 11 blade and cartilage scissors until the desired profile is achieved. **F**, If necessary, the upper lateral cartilages can be trimmed after dissecting and preserving the mucosa to create junction tunnels for the placement of spreader grafts.

Continued

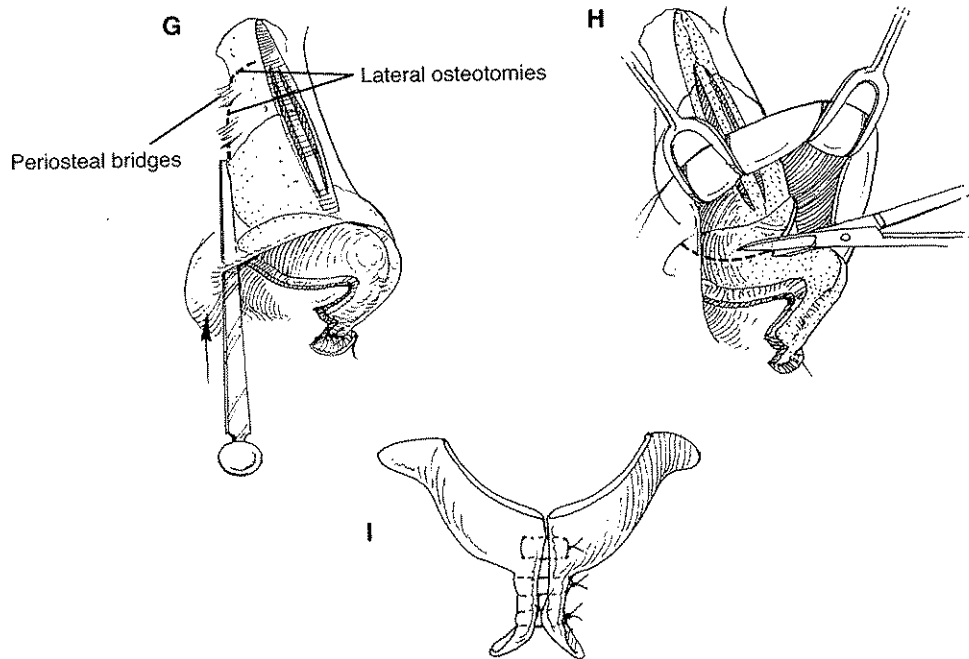


Fig. 34-5, cont'd **G**, Lateral osteotomies are performed to close the open roof from the dorsal reduction. The 2 mm osteotome is used to make perforating cuts at the junction of the nasal bones and maxilla. At the level of the medial canthus, the osteotome is turned 90 degrees to complete the osteotomy. Periosteal attachments are preserved. **H**, The lower lateral cartilages are trimmed, preserving the mucosa and 4 mm of rim for airway support. Care is taken to preserve the upper lateral cartilage attachments to the septum at the nasal valve. **I**, The footplates and domes are sutured together to increase projection and decrease the width of the tip.

Box 34-2 Key Steps of Operative Technique

- Block the nasal field with mepivacaine.
- Perform a sphenopalatine block.
- Use an open approach.
- Follow this stepwise plan: septum, dorsum, osteotomy, middle vault tip, and suture support.
- Postoperatively, administer steroidal agents, keep the patient's head elevated, and apply cold packs.

The wound is irrigated with antibiotic solution and all intranasal incisions are closed with mild chromic suture. The stairstep incision is aligned precisely and closed using 5-0 Prolene. No packing is used. SteriStrips and a thermoplastic dressing are applied. Routine postoperative oral antibiotic agents, analgesics, and a steroid dose pack are given. Patients are allowed to shower. Cold packs are used for 36 hours, and head elevation of 20 degrees is recommended for 7 days. All dressings and sutures are removed at 1 week. Normal activity, including running and swimming, are allowed after 1 week. Direct nasal trauma must be avoided for 6 weeks. The key steps of the operative technique are reviewed in *Box 34-2*.

Techniques to Address Specific Tip Deformities

There are many types of tip deformities, which must be approached on a case-by-case basis (*Box 34-3*). Time-tested reduction and grafting techniques need to be creatively applied depending on the particular aesthetic or structural need of the patient.^{20,21} Most commonly, adolescent tip deformities are bulbous or bifid, plunging or asymmetrical, and they can occur as a single deformity or in combination.^{27,28} In the sequential rhinoplasty approach described in the previous section, the tip is addressed as one of the final steps. This allows the tip projection and rotation to be adjusted according to the bony dorsal and middle vault height and width.

Bulbous and bifid tips result from a variety of anatomic factors.^{20,28,29} Skin thickness and texture can affect tip aesthetics¹⁸ (*Figs. 34-6* and *34-7*). Patients with particularly thick sebaceous skin may benefit from dermatologic intervention before rhinoplasty. Thick sebaceous skin can make the tip appear more bulbous. Fibrofatty tissue is often found between the medial crura of the lower lateral cartilages, thus splaying them out. The tip is addressed as outlined in the pre-

Box 34-3 Common Tip Deformities

- Bulbous tip
- Bifid tip
- Asymmetrical tip
- Plunging tip

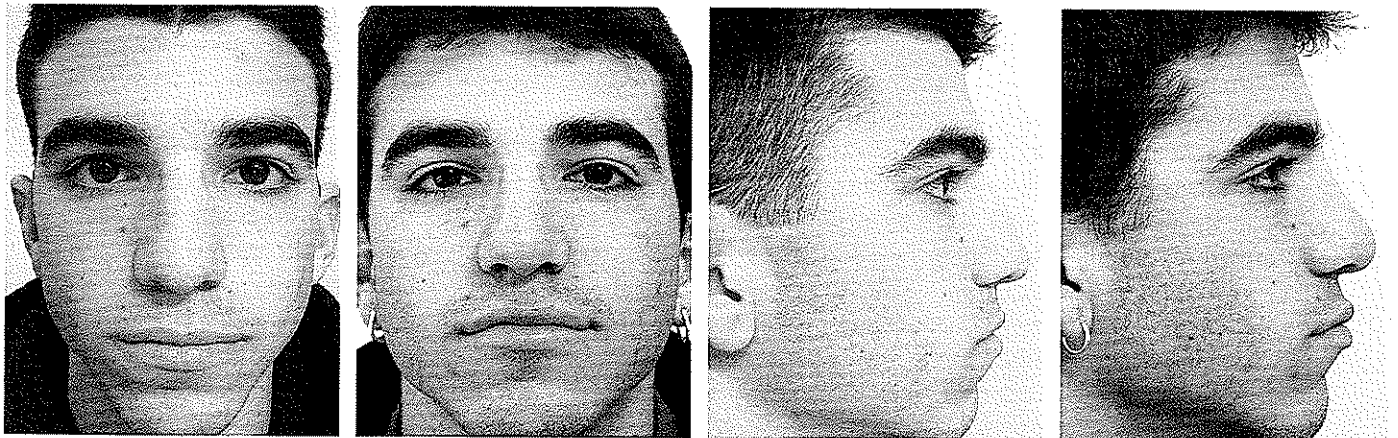


Fig. 34-6 This 16-year-old patient had a broad, amorphous nose, dorsal hump, and poorly defined tip. He underwent reductive rhinoplasty to achieve the desired dorsal height. Maximal lower lateral cartilage reduction was performed, leaving a 4 mm intact rim. Bilateral alar spreader grafts were used to define dorsal aesthetic lines, as well as stacked, Peck-type grafts to define the tip. Excising the floor of the nose reduced the basal width.



Fig. 34-7 This 18-year-old patient had tip bifidity, slight saddling of the middle vault, and a broad nasal base. Lateral osteotomies, lower lateral cartilage dome reduction, and suturing of the medial crura to each other were performed to decrease the overall nasal width. Dorsal septal graft excisions of the base of the nose were also performed. Shield graft was used to define the tip. Diamond-shaped excisions of the base of the nose were also performed.

vious section, that is, after the septum, dorsum, middle vault, and osteotomy maneuvers are completed. Tip work is inherently delicate, often involving precisely positioned cartilage grafts; therefore it is done just before the skin envelope is closed to avoid suture disruption or graft displacement. Basic maneuvers include trimming the cephalic margins of the upper lateral cartilages, weakening the lateral crus, and cartilage grafting to highlight tip-defining points.^{10,11,19,27-29}

When trimming the cephalic margins, a 4 mm width must be preserved to prevent inspiratory collapse at the nasal inlet (see Fig. 34-5, *H*). The medial crura are then sutured to each other starting at the footplates and extending to the domes (see Fig. 34-5, *I*). This decreases the tip width and increases projection. If the width of the tip remains too wide along the lateral crus after cephalic trimming and suturing of the domes, the lateral crura can be weakened or *bruised* using a shielded cartilage crusher (Fig. 34-8). This maneuver converts the convex lateral crus projection into a slightly concave surface. From the frontal view, the result is seen as a decrease in tip width. Various shapes of autologous septal grafts can be added to the tip to create tip-defining points (Fig. 34-9; see also Figs. 34-5, *H* and *I* and 34-8). I primarily use Sheen shield grafts and Peck tip grafts.^{10,11,20,30,31} It is important to bruise these grafts using a cartilage crusher to prevent a long-term edge effect as the skin adheres to the grafts.

If the graft is thick, the edges should also be beveled (Fig. 34-10). The degree of bruising and/or beveling is determined by the thickness of the overlying tip skin, with thicker skin requiring less softening of the graft edges.²⁹⁻³² After all incisions have been closed, the alar base width is addressed (Fig. 34-11). Tip projection, columellar grafts, domal sutures, and rotation all influence the alar width and shape; therefore those variables need to be eliminated before addressing basal width.¹¹ If at all possible, external incisions are avoided to prevent visible scars. In cases of extreme alar flaring, they can be useful and should be placed at the juncture of the nasal and facial skin. I prefer to reduce the base width by removing a diamond-shaped section of the nasal floor (see Fig. 34-7). The wider the diamond, the greater the amount of basal width reduc-

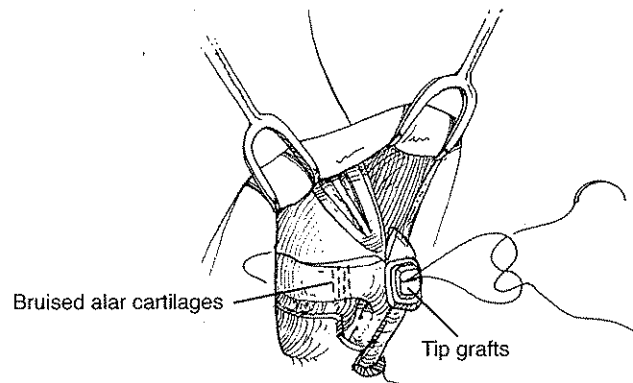


Fig. 34-8 Tip grafts are applied to the domes to provide more tip definition and highlights. If the convexity of the lateral crura is excessive, they can be gently bruised with a guarded cartilage crusher (protecting the mucosa) to achieve a slightly concave curvature. The result is a decrease in perceived tip width on the frontal view.

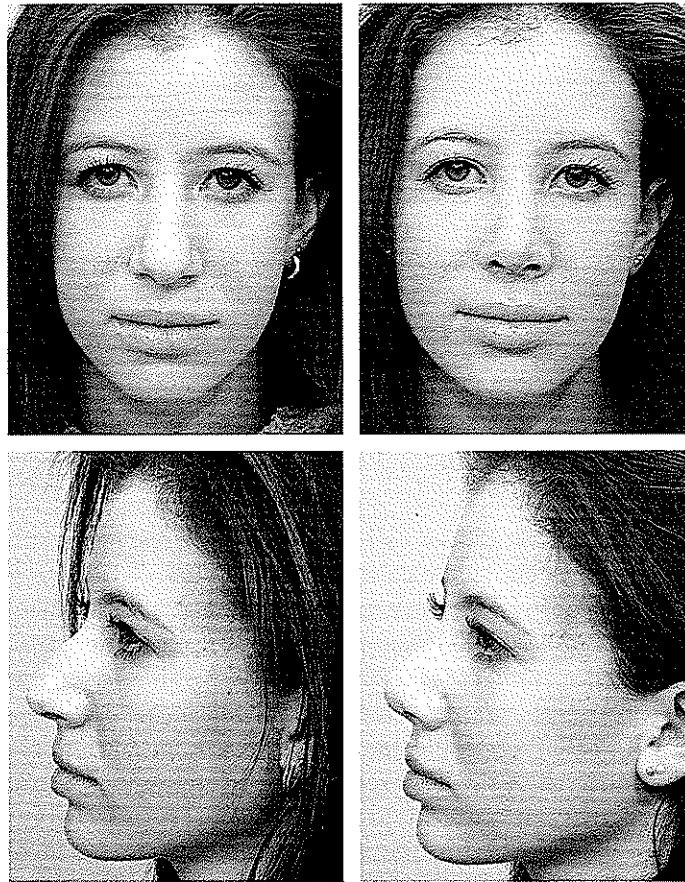

Fig. 34-9 This 15-year-old girl had a broad tip and slight nasal hump. The dorsum was carefully reduced with lateral osteotomies to close the open roof. The tip was refined by reducing the domes, bruising the lateral crura to increase their convexity, suturing the domes, and adding shield graft for definition.

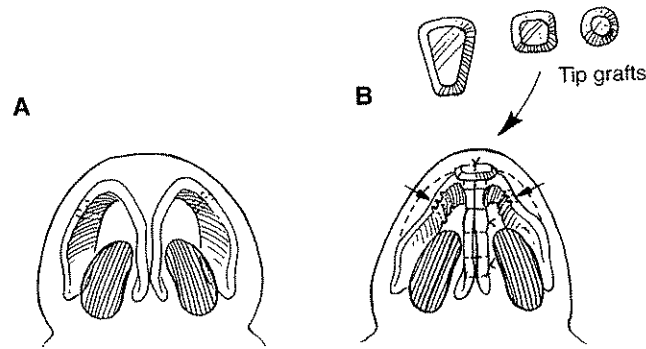


Fig. 34-10 A, Correction of a boxy or bifid tip. The medial crura and domes are splayed apart. B, The combination of crural sutures, tip grafts, and lateral crural bruising (*dashed lines*) is used to increase tip projection and definition, and to correct bifidity. Arrows show inward movement of lateral crura after bruising.

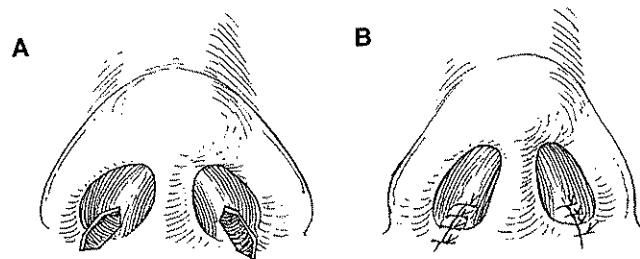


Fig. 34-11 As the last step in aesthetic rhinoplasty, the width of the nasal base is evaluated. A, Diamond-shaped base excisions including skin and mucosa are carried out using a No. 11 blade. B, Careful suturing of the edges results in a decreased base width, with the scars being almost entirely within the nostrils.

tion. Careful alignment of the nasal floor roll can make these scars almost invisible¹¹ (see Figs. 34-4 and 34-7). This maneuver should be performed sequentially to ensure symmetry and avoid overresection. The external portions of the excisions are closed with 5-0 nylon suture and the intranasal portion is closed with resorbable sutures.

The plunging tip can be caused by overgrowth of the dorsal septum, an absent or retracted caudal septum, or deficient footplates.^{11,27,29} It can result in an acute nasolabial angle, often worsening with smiling, with a resulting profile deformity.¹⁹ The external rhinoplasty exposure allows direct visualization and analysis of the deformity.²⁰ The dorsal septum is trimmed as previously described allowing cephalic rotation of the tip (see Fig. 34-5, E). In many cases, this rotation suffices to achieve the desired nasolabial angle. In cases of a weak, retracted, or absent caudal septum or footplates, a caudal columellar strut can be helpful (*Fig. 34-12*). I have found that the cartilaginous septum is ideal for this purpose because a 4 mm thick by 3 cm long strut is usually available. The strut acts as a central structural pillar to which the footplates and medial crura can be attached (see Fig. 34-12, B). A pocket is created between the footplates and the skin to the nasal spine. Care must be taken to ensure that the strut is in contact with the nasal spine area to maintain stability (see Fig. 34-12, B). The vector for strut placement needs to be carefully selected to prevent overrotation or underrotation of the tip.²⁰ Once the appropriate vector is de-

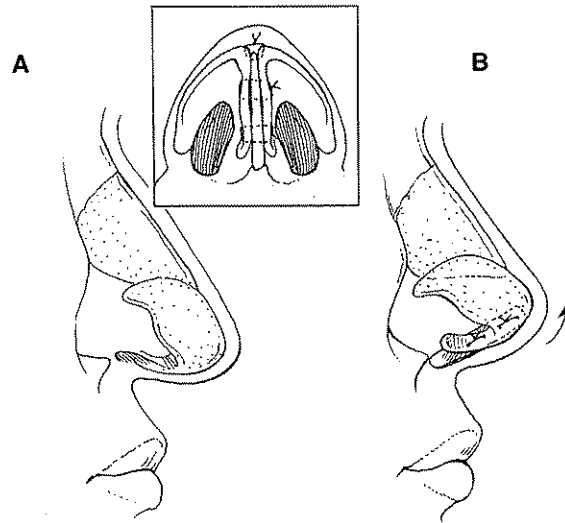


Fig. 34-12 A, Columellar strut grafts can be useful in cases of insufficient tip support that result in an acute nasolabial angle. B, Placement of the strut raises the tip, and the angle of placement against the nasal spine influences the resulting nasolabial angle. The tip of the graft should not project beyond the native cartilages (*insert*).

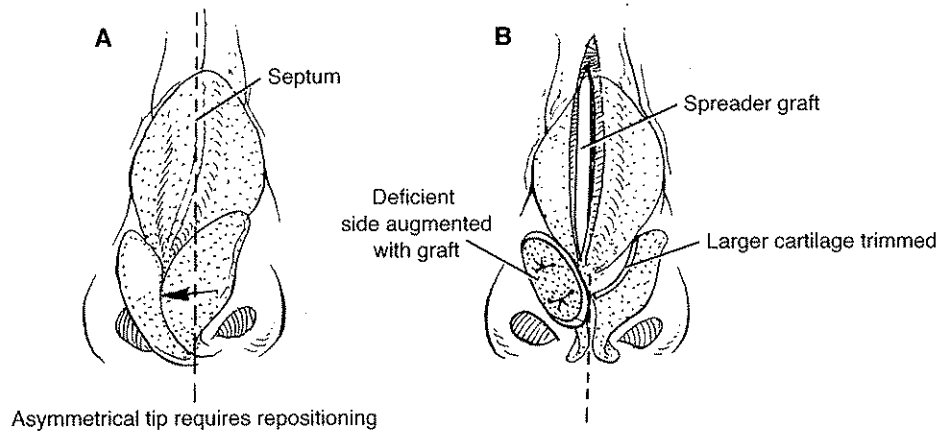


Fig. 34-13 A, A twisted nasal deformity requires repositioning all components toward facial and dental midlines. B, Correction includes adding spreader graft in the middle vault to disguise dorsal septal deviation, as well as combined tip resection and contralateral augmentation.

terminated—one that gives the desired nasolabial angle and nostril show—the strut is sutured to the footplates with 5-0 PDS (see Fig. 34-12, B). The distal tip of the columellar graft should not project beyond the native domes.

An asymmetrical tip can be very challenging (Fig. 34-13, A). It can be caused by asymmetrical growth, trauma, or previous surgery.^{20,29} After external exposure, the dimensions and shape of the tip cartilages are evaluated.²⁰ The larger cartilage is trimmed and the smaller cartilage is augmented with autologous cartilage (Fig. 34-13, B). If the asymmetry is caused by malposition of the lateral crus, it can be sharply dissected and repositioned in a new soft tissue pocket. If the

Box 34-4 Addressing Tip Deformities

- Preserve the rim of lower lateral cartilage.
- Suture the medial crura to decrease the width.
- Perform protected crushing to weaken the lateral crus.
- Use autologous grafts for tip definition.
- Use columellar strut graft for a plunging tip.
- Use a diamond-shaped resection of the floor of the nose to decrease the width.

asymmetry is caused by a difference in shape of the crura, I prefer augmentation with autologous grafts. If one cartilage is concave and the other is convex, then the convex side can be bruised to break the spring of the cartilage or the concave side can be grafted (see Figs. 34-8 and 34-13, *B*). Areas of concern when addressing tip deformities are presented in *Box 34-4*.

Techniques to Address Specific Dorsum Deformities

Before performing maneuvers to address aesthetic deformities of the nasal dorsum, both the nasal bone component and cartilaginous middle vault must be carefully evaluated and properly treated.²⁹ Aesthetic surgery of the nasal dorsum can be divided into the following three general categories: (1) Reduction of an overly prominent dorsum is the most common procedure; (2) Augmentation of a low dorsum or saddlenose deformity is occasionally necessary (see Fig. 34-7); and (3) Correction of an asymmetrical dorsum, which may be associated with a prominent or deficient dorsum, is the most difficult condition to correct^{26,31,33,34} (*Box 34-5*).

Reduction of the Dorsum

Reduction of the dorsum was previously discussed in this chapter. In the adolescent, I recommend very conservative dorsal reduction. In female patients, a very gentle, slightly concave dorsum is ideal, avoiding a “scooped” appearance.^{10,11,20} In males, a straight profile is preferred to preserve a masculine nasal appearance. Avoid damaging the attachments of the upper and lower lateral cartilages to the septum during cartilaginous reduction, because this can compromise the nasal valve (see Fig. 34-1). The attachments of the upper lateral cartilages to the nasal bones need to be preserved to avoid an inverted-V deformity of the dorsum.^{10,11} The mucosa can be protected by dissecting it before the cartilaginous reduction (see Fig 34-5, *E*).

Augmentation of the Dorsum

Augmentation of the dorsum may be necessary in primary or secondary deformities to achieve a balanced nasal profile.^{32,34} Setting the proper dorsal height allows correct tip sculpting and positioning and should precede tip adjustment.²³ Only autologous materials are recommended for dorsal augmentation.^{30,32,35} Septal cartilage, conchal cartilage, and rarely costal cartilage may be required (Figs. 34-14 and 34-15; see also Fig. 34-13). Regardless of the type of autologous cartilage used, it must be secured to the underlying tissues. This can generally be accomplished with direct suture techniques by elevating a pocket over the dorsum that is proportionate to the size of the graft. Rarely, when using costal cartilage, two radix K-wires are required. Septal car-

Box 34-5 Deficiencies of the Nasal Dorsum and Deformities of the Middle Vault

- Low dorsum and radix
- Saddle nose deformity
- Asymmetry of the dorsum and middle nasal vault

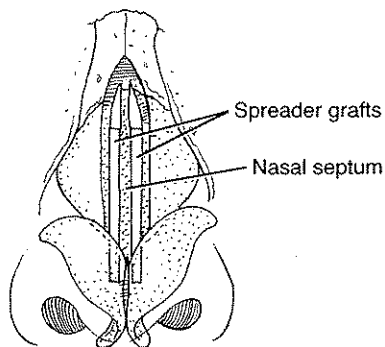


Fig. 34-14 Spreader grafts are useful to obtain optimal dorsal aesthetic lines and to support the nasal valve.

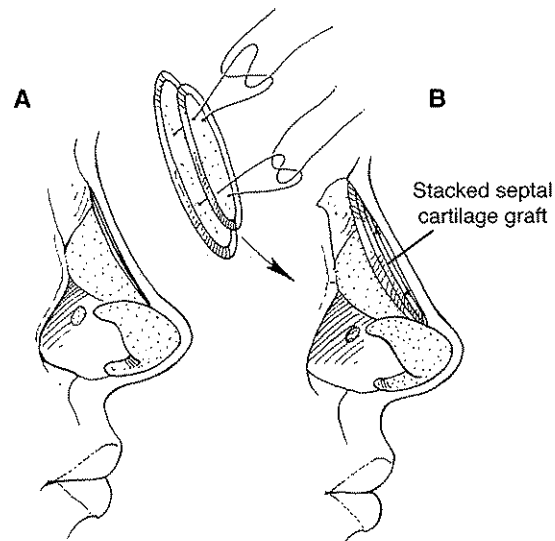


Fig. 34-15 **A**, This saddle nasal deformity is corrected with a septal sheet graft. The edges should be beveled and bruised to prevent visible edges. **B**, Stacking the grafts can provide up to 4 mm of dorsal projection.

tilage can be used to correct moderate dorsal deformities that require 2 to 4 mm of augmentation.¹⁵ The edges should be beveled and bruised with a cartilage crusher to avoid a subcutaneous edge effect, especially in patients with thin skin. Septal cartilage has the advantages of being locally available, not prone to warping, and quite durable. Conchal cartilage can be used when septal cartilage is not available. It can be shaped with sutures to provide volumetric augmentation or crushed to into a thin sheet. It tends to have a memory and will curl over time toward the intact perichondrium. In cases with a severe saddlenose deformity, costal cartilage is preferred.³⁵ Very rarely, this severe deformity presents a primary aesthetic problem. Most commonly, it is a secondary deformity resulting from trauma, previous surgery, or a congenital deformity. Care is taken to remove all of the perichondrium during the shaping process to prevent warping. Occasionally, a longitudinal K-wire is used to prevent warping. Shaped costal grafts are used for large augmentations, and temporary fixation to the nasal process of the frontal bone is achieved with K-wires to prevent displacement.

Asymmetries of the Dorsum

Asymmetries of the dorsum can be very challenging to correct and can occur as a primary deformity or result from trauma or previous nasal surgery. They may be caused by nasal bone deformities, septal deformities, or both. Asymmetries are characterized by the lack of a straight light reflex on the frontal view.^{26,28,34} Bony deformities are generally corrected by osteotomies of the nasal bones as described previously in the chapter. In cases of a one-sided concavity, the affected nasal bone can be outfractured. In cases of convex nasal bone deformities, the affected side can be infractured. The previously described internal nasal osteotomy technique allows stable bony positioning by preserving the nasal bone's periosteal attachments. Asymmetries of the cartilaginous dorsum require thorough analysis and careful correction.^{10,11,20,33} The dorsal septum can easily be overresected, resulting in a saddlenose deformity. Spreader grafts can be shaped to disguise dorsal deformities rather than risk an iatrogenic saddlenose^{12,14} (see Figs. 34-4 and 34-6). They can be applied unilaterally to fill in a concave deformity and achieve a visually straight nasal appearance (see Fig. 34-13). These grafts can be shaped into different thicknesses and lengths. The amount of spreader graft projection can be controlled by placing it higher or lower along the dorsal septum, which will influence the dorsal light reflex (see Fig. 34-14). In addition, they can be used to add width and internal diameter at the nasal valve level in cases of inspiratory alar valve collapse.³⁶ Issues to consider when addressing deformities of the dorsum are presented in *Box 34-6*.

Box 34-6 Addressing Deformities of the Dorsum

- Perform conservative dorsum reduction.
- Preserve attachments of the upper lateral cartilages.
- Preserve the mucosa.
- Use the septum or concha for mild dorsal deformities.
- Use shaped costal cartilage for severe saddlenose deformities.
- Use spreader grafts for middle vault asymmetry.

Adjunctive Procedures

In cases of retromicrogenia and/or retromicrognathia, the position of the mandible has a major influence on the perceived nasal proportions as well as neck aesthetics.³⁷ These anatomic findings should be discussed with the patient during the preoperative consultation. Lateral cephalometric radiographs along with computer simulation of rhinoplasty and alterations in the chin projection can be very helpful in educating the patient about potential adjuvant procedures.¹²⁻¹⁴ Overreducing the nasal profile to fit the repositioned chin point should be avoided. I am not in favor of chin implants in adolescents because of potential infection, displacement, or migration of the implant into the bone. I prefer to harmonize the profile in patients with retromicrogenia using osseous genioplasty (*Figs. 34-16 and 34-17*). In addition to a lateral cephalogram,

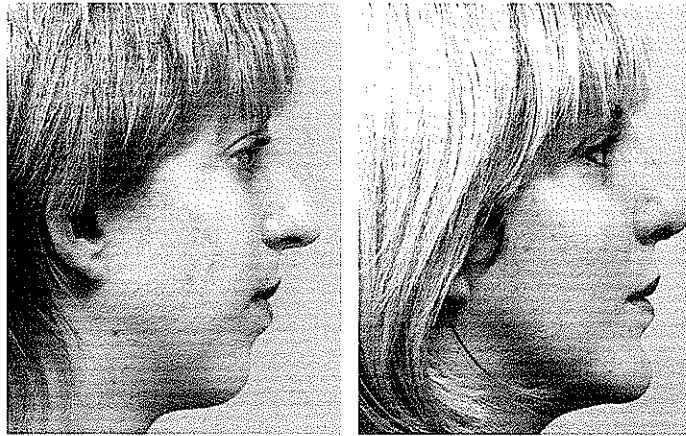

Fig. 34-16 This 18-year-old patient had excessive nasal projection and retromicrogenia causing disharmony. Reductive rhinoplasty was combined with osseous genioplasty and an 8 mm advancement to balance her profile.

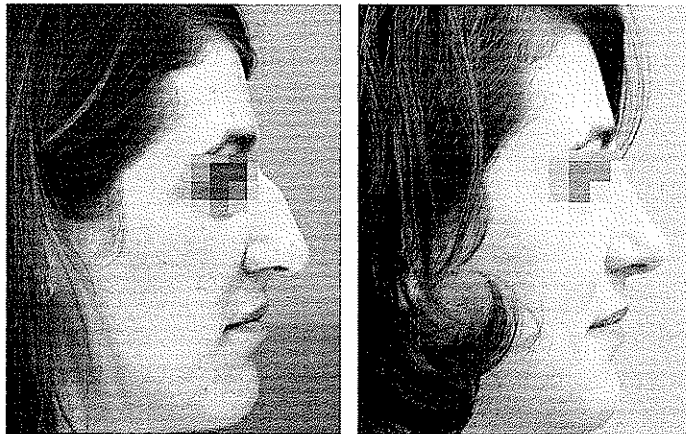


Fig. 34-17 This 19-year-old patient had a large dorsal hump and retrogenia. Her profile was balanced with reductive rhinoplasty and osseous genioplasty with a 6 mm advancement.

a panoramic radiograph is taken to check for periapical dental problems, preexisting root canals, or supernumerary teeth. A sublabial approach with careful preservation of at least 5 mm of bone below the mental foramen reduces the risk of damage to the mental nerve or tooth apices.³⁸ The midline is marked with the oscillating saw, and the anterior osteotomy is made parallel to the occlusal plane well below the teeth apices (*Fig. 34-18*; see also *Fig. 34-15*). The posterior and lateral parts of the osteotomy are completed using the reciprocating saw. The angle of the osteotomy is used to determine whether lengthening or shortening of the vertical chin dimension is needed and should be decided preoperatively.³⁸ Fixation is achieved using prefabricated titanium plates bent to provide the desired degree of advancement. The mentalis muscle is reapproximated and the chin is taped for 5 days postoperatively. The net effect of osseous genioplasty is to advance the chin point and tighten the muscles of the neck, improving neck aesthetics (see *Fig. 34-18*). Potential complications, although very rare, include damage to the mental nerve, marginal mandibular nerve, and tooth apices, as well as stress fractures of the mandible. Issues to consider when addressing retromicrogenia and/or retromicrognathia are listed in *Box 34-7*.

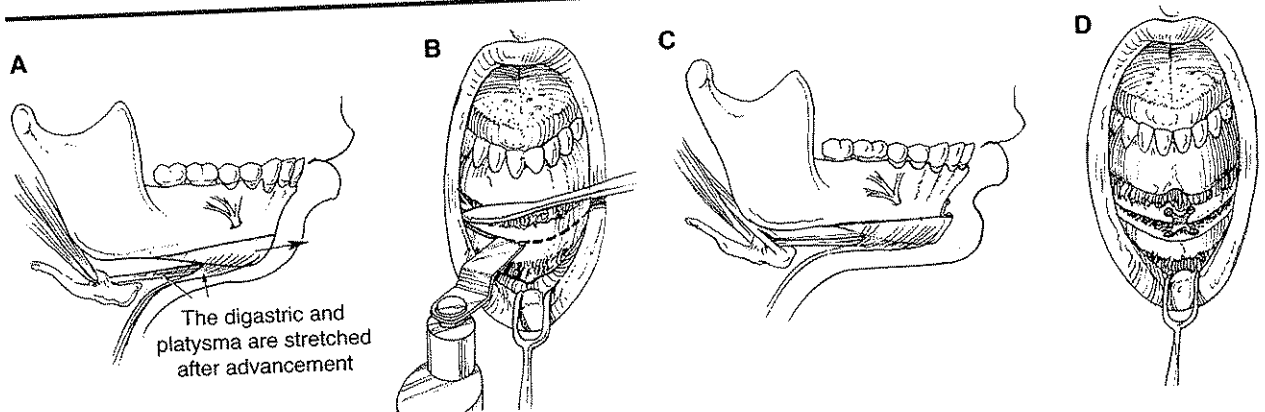


Fig. 34-18 A, Osseous genioplasty can enhance the cervicomental angle and is often combined with rhinoplasty to balance the profile. B, The inferior alveolar nerve and tooth apices are avoided by making the transverse osteotomy at least 5 mm below the mental foramen. C, Because the cervical muscles are still attached, bringing the chin point forward results in a more defined cervicomental angle as well as a balanced profile. D, The osteotomy segments are stabilized with a previously bent titanium plate to provide the desired advancement as determined on preoperative analysis.

Box 34-7 Addressing Retromicrogenia and/or Retromicrognathia

- One major goal is to restore facial proportions.
- Use autologous tissue (patient's chin bone).
- Perform the osteotomy 5 mm below the mental foramen.
- Use rigid fixation.
- Provide lip support by taping postoperatively.

COMPLICATIONS

Avoiding the unfavorable result should always be the foremost goal in aesthetic rhinoplasty, particularly in adolescent rhinoplasty (**Box 34-8**). Careful preoperative planning, stepwise execution, and conservation of tissues can minimize postoperative surprises.³⁹ Common errors include over-resection of the lower lateral cartilages, resulting in a pinched appearance and often airway compromise. Aggressive dorsum resection should be avoided to prevent a saddlenose deformity. Supratip deformities can be caused by scar tissue filling the dead space, or inadequate resection of the dorsal septum at its juncture with the lower lateral cartilages.^{10,11,39} Dead space can be obliterated with crushed septal grafts, and careful microreduction of the septum can ensure a pleasing profile. Nostril asymmetries can be avoided by centering the caudal septum and/or columellar grafts. Nostril width correction should take place at the end of the case after all incisions have been closed. Incisions placed along the floor of the nose are nearly invisible and prevent alar rim scars. Visible or palpable step-offs are avoided by careful approximation of both exterior step incisions and intranasal incisions.

The patient may be unhappy with the result despite good surgical planning and execution—this is sometimes unavoidable.⁴⁰⁻⁴² Technical factors such as healing, infection, or surgical miscalculations can cause this result. In most instances, this disappointment results from poor preoperative communication among the surgeon, patient, and parents that resulted in unrealistic expectations. Thorough and honest preoperative discussions with all vested parties present, the use of computerized imaging, and presenting photographs of previous rhinoplasty patients can avoid postoperative conflicts. Occasionally, an adolescent's depression or other mental disturbance causes him or her to focus on a minor postrhinoplasty problem, and the surgeon becomes a lightning rod for the patient and family's frustration. In these cases, psychological counseling may be indicated before any revision surgery is contemplated.

If secondary rhinoplasty is unavoidable, I suggest waiting at least 9 months to allow healing to take place before considering a reoperation. In general, secondary defects are addressed in a manner similar to those used for primary rhinoplasty. The techniques that are most appropriate for the specific problem are used. A careful preoperative evaluation is performed, photographic documentation is shared with all parties, and thorough informed consent is obtained.⁸

Box 34-8 Avoiding Common Errors and Unfavorable Results

- Careful preoperative planning
- Conservative resection
- Obliteration of dead space
- Careful incision closure

CONCLUSION

Adolescence is a critical period of development both physically and mentally, and self-image can be adversely affected by nasal deformities. Adolescent rhinoplasty can result in gratifying results that greatly enhance the psychosocial and physical well-being of the patient. In many cases, both functional and aesthetic improvement can be achieved. A thorough preoperative evaluation and discussion of expectations and computerized imaging can avoid misunderstandings that lead to postoperative disappointment. A stepwise approach to nasal surgery is important, with an emphasis on a conservative but thorough approach to the patient's aesthetic and functional needs. Following these steps allows the surgeon to fully address aesthetic and functional nasal concerns in a logical and systematic fashion to obtain the best possible outcome. Adjuvant osseous genioplasty of the mandible can be a powerful tool when combined with rhinoplasty to achieve optimal facial aesthetic balance.

KEY POINTS

- An adolescent's self-esteem is greatly influenced by physical appearance.
- The nose is the focal point of facial aesthetics; therefore it is a key component in establishing harmonious facial balance.
- For all rhinoplasty patients, especially adolescents, communication between the patient and the plastic surgeon is one of the keys to a successful result. Reasonable expectations must be discussed preoperatively with the patient and his or her family.
- A stepwise approach to rhinoplasty is recommended, allowing a sequential surgical treatment plan that is predictable and reproducible.
- The overall facial balance is the key to the patient's satisfaction. Adjuvant maneuvers such as osseous genioplasty should be considered in patients with certain anatomic features.

REFERENCES—With Key References Annotated

1. Fodor P. Aesthetic rhinoplasty in early adolescence. *Aesthetic Plast Surg* 4:207-216, 1988.
2. Hillhorst M. Philosophical pitfalls in cosmetic surgery: a case of rhinoplasty during adolescence. *Med Humanit* 28:61-65, 2002.
3. Weston P. Attitudes of adolescents about cosmetic surgery. *Ann Plast Surg* 50:628-630, 2003.
4. Babuccu O, Latifoglu O, Atabay K, et al. Sociological aspects of rhinoplasty. *Aesthetic Plast Surg* 27:44-49, 2003.
5. Correa A, Sykes J, Ries W. Considerations before rhinoplasty. *Otolaryngol Clin North Am* 32:7-14, 1999.
6. Akgüner M, Bartuçı A, Karaca C. Adolescent growth patterns of the bony and cartilaginous framework of the nose: a cephalometric study. *Ann Plast Surg* 41:66-69, 1998.
7. Ortiz-Monestario F, Olmedo A. Corrective rhinoplasty before puberty: a long-term follow up. *Plast Reconstr Surg* 68:381-391, 1981.
8. Gorny M. Claims prevention for the aesthetic surgeon: preparing for the less than perfect outcome. *Facial Plast Surg* 18:135-142, 2002.
9. Lupo G. The history of aesthetic rhinoplasty: special emphasis on the saddle nose. *Aesthetic Plast Surg* 5:309-327, 1997.
10. Rees T, ed. *Aesthetic Plastic Surgery*. Philadelphia: WB Saunders, 1980.
This wonderfully illustrated text provides excellent anatomic drawings for basic techniques in aesthetic rhinoplasty.
11. Sheen J, Sheen A. *Aesthetic Rhinoplasty*, 2nd ed. St Louis: Mosby-Year Book, 1998.
This is an excellent guide for analyzing nasal deformities and planning the most appropriate treatment.
12. Guyron B. Precision rhinoplasty. I. The role of life size photographs and soft tissue cephalometric analysis. *Plast Reconstr Surg* 81:489-499, 1988.
13. Fruscella P. Cephalometric analysis and postoperative results in aesthetic rhinoplasty. *Aesthetic Plast Surg* 21:79-85, 1997.
14. Bronz G. The role of the computer imaging system in modern aesthetic plastic surgery. *Aesthetic Plast Surg* 3:159-163, 1999.
15. Curtis E, Gargan T, Courtiss G. Nasal physiology. *Ann Plast Surg* 13:214-223, 1984.
16. Lam S, Williams E. Anatomic considerations in aesthetic rhinoplasty. *Facial Plast Surg* 18:209-214, 2002.
17. Peck G, Michelson L. Anatomy of aesthetic surgery of the nose. *Clin Plast Surg* 14:737-748, 1987.
This is a wonderful clinical anatomy guide for performing aesthetic rhinoplasty.
18. Broadbent T, Woolf R. Basic anatomy: clinical application in rhinoplasty. *Ann Plast Surg* 13:76-89, 1984.
19. Kocer U. Effect of aesthetic rhinoplasty on respiratory functions. *Aesthetic Plast Surg* 25:202-206, 2001.
20. Johnson C, Toriumi D. *Open Structure Rhinoplasty*. Philadelphia: WB Saunders, 1990.
This is a well-illustrated anatomic guide to the open approach in rhinoplasty.
21. de la Fuente A, Martin del Yerro J. Management of the septum during rhinoplasty. *Aesthetic Plast Surg* 19:455-461, 1995.
22. Constantain M. Experience with a three point method for planning rhinoplasty. *Ann Plast Surg* 30:1-12, 1993.
23. Williams E. A systematic, graduated approach to rhinoplasty. *Facial Plast Surg* 18:215-222, 2002.
24. Daniel RK, Lessard ML. Rhinoplasty: a graded aesthetic-anatomical approach. *Ann Plast Surg* 13:436-451, 1984.
25. Giacomarra V, Russolo M, Arnez Z, et al. External osteotomy in rhinoplasty. *Laryngoscope* 111:433-438, 2001.
26. Rohrich R, Muxaffar A, Janis J. Component dorsal hump reduction: the importance of maintaining dorsal aesthetic lines in rhinoplasty. *Plast Reconstr Surg* 114:1298-1308, 2004.
This article provides an important conceptual basis for improving dorsal aesthetics.
27. Daniel R. The nasal tip: anatomy and aesthetics. *Plast Reconstr Surg* 89:216-224, 1992.
The author correlates anatomy and tip aesthetics with surgical maneuvers.
28. Rohrich R, Adams WP. The boxy nasal tip: classification and management based on alar cartilage suturing techniques. *Plast Reconstr Surg* 107:1849-1863, 2001.
29. Kamer F, Pieper P. Nasal tip surgery: a 30 year experience. *Facial Plast Surg Clin North Am* 12:81-92, 2004.
30. Kamer F, Churukian M. Shield graft for the nasal tip. *Arch Otolaryngol* 110:608-610, 1984.
31. Ortiz-Monestario F, Olmedo A, Oscoy L. The use of cartilage grafts in primary aesthetic rhinoplasty. *Plast Reconstr Surg* 67:597-605, 1981.

32. Cardenas-Camarena L, Guerrero M. Use of cartilaginous autografts in nasal surgery: 8 years of experience. *Plast Reconstr Surg* 103:1003-1014, 1999.
33. Constantain M. An algorithm for correcting the asymmetrical nose. *Plast Reconstr Surg* 83:801-811, 1989.
34. Rorich R, Hollier L. Use of spreader grafts in the external approach to rhinoplasty. *Clin Plast Surg* 23:255-262, 1996.
35. Song C, Mackay D, Chait L, et al. Use of costal cantilever grafts in negroid rhinoplasties. *Ann Plast Surg* 27:201-209, 1991.
36. Schlosser R, Park S. Surgery for the dysfunctional nasal valve. Cadaveric analysis and clinical outcomes. *Arch Facial Plast Surg* 2:105-110, 1999.
37. Greer S, Matarasso A, Wallach SG, et al. Importance of the nasal-to-cervical relationship to the profile in rhinoplasty surgery. *Plast Reconstr Surg* 108:522-531, 2001.
38. Kawamoto H. Osseous genioplasty. *Aesthetic Surg J* 20:509-516, 2000.
39. Holt G, Garner E, McLarey D. Postoperative sequelae and complications of rhinoplasty. *Otolaryngol Clin North Am* 20:853-876, 1987.
40. Guyuron B, Bokhari F. Patient satisfaction following rhinoplasty. *Aesthetic Plast Surg* 20:153-157, 1996.
41. Constantain M. Four common anatomic variants that predispose to unfavorable rhinoplasty results: study based on 150 consecutive secondary rhinoplasties. *Plast Reconstr Surg* 105:316-331, 2000.
42. Moses S, Last U, Mahler D. After aesthetic rhinoplasty: new looks and psychological outlooks on post-surgical satisfaction. *Aesthetic Plast Surg* 8:213-217, 1984.