

## Piriform Aperture Stenosis: A Rare Cause of Neonatal Airway Obstruction

Fernando D. Burstein, MD  
Steven R. Cohen, MD

Because neonates are obligate nasal breathers, neonatal nasal obstruction may have serious consequences. Prompt diagnosis and appropriate treatment are essential to avoid severe hypoxia. Anterior inlet, piriform aperture stenosis is an extremely rare cause of neonatal nasal airway obstruction and can easily be confused with choanal atresia or stenosis. Computed tomography with direct coronal scans is the best means of establishing a definitive diagnosis. We present our experience with four neonates having nearly complete piriform aperture stenosis. Prompt surgical enlargement of the nasal inlet through an upper buccal sulcus approach is recommended.

Burstein FD, Cohen SR. Piriform aperture stenosis: a rare cause of neonatal airway obstruction. *Ann Plast Surg* 1995;34:56-58

From the Center for Craniofacial Disorders, Scottish Rite Children's Medical Center, Atlanta, GA.

Received Aug 15, 1994. Accepted for publication Sep 9, 1994.

Address correspondence to Dr Burstein, Center for Craniofacial Disorders, Scottish Rite Children's Medical Center, 5455 Meridian Mark Rd, Suite 200, Atlanta, GA 30342.

Nasal airway obstruction in the neonate can result in apnea and may be life threatening [1]. Prompt recognition in the delivery room or nursery is essential. Common causes include septal displacement or hematoma, displaced nasal bone fractures, and choanal atresia or stenosis [1, 2]. Congenital piriform aperture stenosis is a rare cause of airway obstruction in the newborn and can be easily mistaken for choanal stenosis or atresia. Both may present as cyclic cyanosis relieved by crying, inability to nurse, or sudden total obstruction. The piriform aperture is the bony nasal inlet and normally represents the narrowest rigid portion of the nasal airway. A very small change in its cross-sectional area can result in a significant increase in nasal airway resistance with a concomitant increase in the work of breathing, often leading to exhaustion. Nasal examination may be difficult because of the small size of the nares.

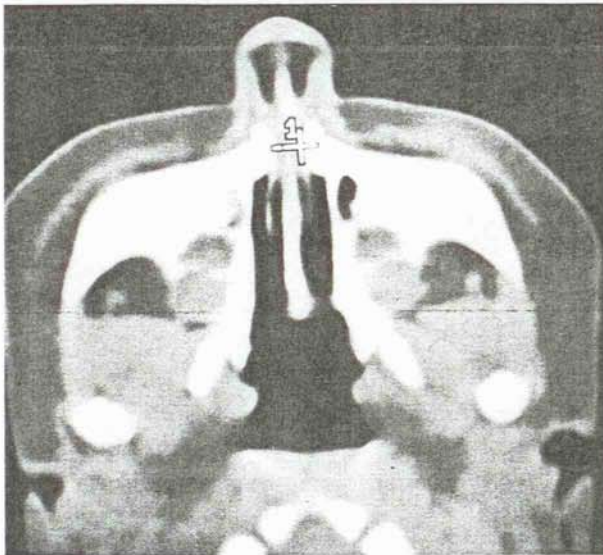
### Patients and Methods

Patients were 2 boys and 2 girls aged 1 to 5 days (mean, 2 days). All patients presented with stridor in the delivery room. In 2 patients, a 6-Fr catheter could not be passed in either naris, and the initial diagnosis of choanal atresia was made. In a third patient, stridor and cyanosis were noted during the first feeding attempt. This neonate required endotracheal intubation. Finally, the fourth neonate fed initially, but increasing stridor developed with the onset of slight nasal congestion. This infant also required endotracheal intubation.

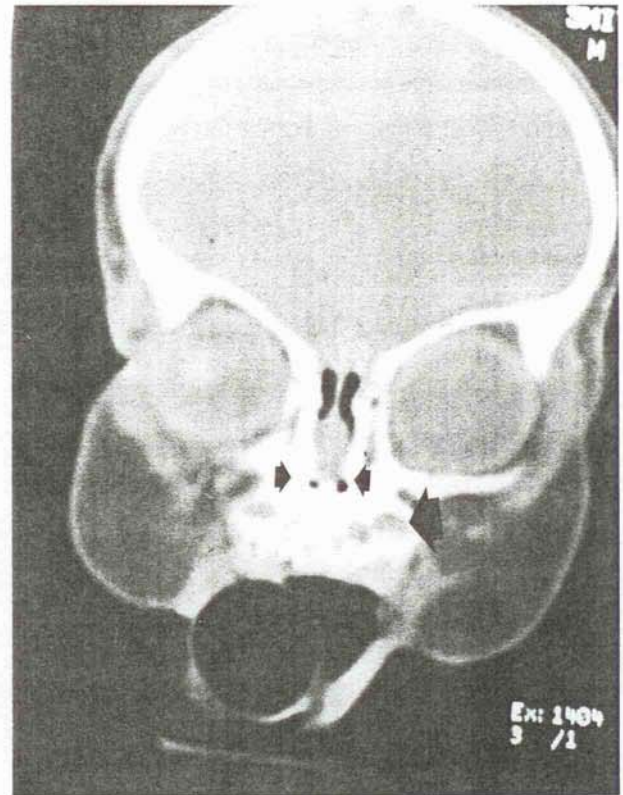
Stable airways, oral pharyngeal or endotracheal, had been obtained in all patients by the time of surgical consultation. The only abnormality noted on examination was the inability to pass a 6-Fr catheter through the anterior naris. There was no evidence of nasal fracture, septal hematoma, or displacement. Computed tomograms were obtained in both the axial and direct coronal planes (Fig 1). Anterior nasal inlet bony stenosis was evident on each scan.

### Surgical Management

One patient was treated with serial dilatation of the anterior naris, vasoconstrictive nasal drops, and frequent suction. Three patients were treated surgically (Fig 2). The upper buccal sulcus was injected with lidocaine .25% and 1:400,000 epinephrine, and a small incision was made in the sulcus using needlepoint electrocautery. Gentle subperiosteal dissection was used to define the bony inlet, which was visibly narrowed in each case. A 2-mm diamond burr was then used to remove slowly a strip of bone at least 1.5 mm wide from the inferior bony inlet along the nasal floor to the lateral nasal process of the maxilla. Great care was taken to prevent damage to the nasal mucosa and tooth bud prominences. Dis-



A



B

Fig 1. (A) Computed tomogram, axial view, showing nasal passages. Note the extreme narrowing (1) at piriform aperture. (B) Computed tomogram, direct coronal view, showing anterior nasal airway. Note the very limited airway space between the nasal septum and bony lateral nasal wall (small arrows). Note also the close proximity of the tooth buds to the lateral nasal wall (large arrow).

section was kept anterior to the inferior turbinate to avoid damage to the nasolacrimal duct. Soft polymeric silicone (Silastic) nasopharyngeal airways were used to maintain nasal airway patency during the period of postoperative edema and were left in place for 5 days. A regimen of vasoconstrictive nasal drops alternating with normal saline drops every 12 hours was used for 5 days and then discontinued without tapering.

### Results

There were no intraoperative or postoperative complications. Follow-up ranged from 6 to 72 months (mean, 36 months). The 3 surgically treated patients have remained asymptomatic without clinical evidence of restenosis. To date, facial growth has appeared to be normal. Normal primary dentition has erupted in all. The nasal inlet size is age appropriate, and all patients can breathe through their nose. The patient treated

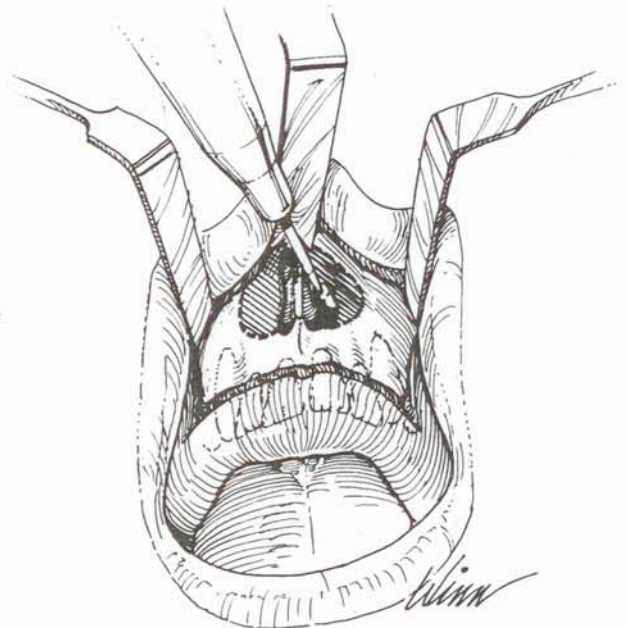


Fig 2. Operative approach to anterior bony inlet through sublabbial incision. Stippled areas represent bony overgrowth impinging on airway. A diamond burr was used to enlarge the aperture, staying above tooth buds.

with dilatation is now 3 years old and continues to have frequent episodes of severe nasal congestion, requiring vasoconstrictive nasal drops. A very narrow nasal inlet is still apparent. Surgical therapy is contemplated in the near future.

## Discussion

Neonates are obligatory nasal breathers until 6 to 8 weeks of life; therefore, the nasal airway is of paramount importance [1, 2]. The critical flow point in the nasal airway is the narrowest diameter, and very slight changes in cross-sectional area will result in tremendous changes in airflow because of the inverse, exponential relationship between flow and diameter. The critical point is thought to be at the nasal valve, the juncture of the cartilaginous septum, and upper and lower lateral cartilages. The cross-sectional area of the nasal valve can be affected by edema or displacement of the septum or lateral cartilages and local vasoconstriction or dilatation of the nasal mucosa. The piriform aperture represents the anterior bony inlet to the nasal cavity and is of a fixed, transverse diameter. It is not generally considered as a possible critical flow point.

Douglas in 1952 [3], Rozner in 1964 [4], and later Shetty [5] described bony inlet stenosis as a cause of nasal airway obstruction in adults. They described a transnasal approach with partial removal of the lateral nasal process of the maxilla with excellent results. The cause in all three reports was thought to be traumatic; however, Shetty speculated that a small number of his patients had experienced excessive growth of the "medial or pyramidal part of the maxillae" resulting in narrowing of the bony inlet. In 1988, Ey and colleagues [6] reported two infants with bony inlet stenosis and airway obstruction who were initially diagnosed as having choanal stenosis. They advocated the use of computed tomography for diagnostic purposes. In 1989, Brown, Myer, and Manning [7] reported congenital nasal piriform stenosis in 6 newborns and advocated surgical enlargement via the sublabial approach.

The cause and long-term significance of this

bony narrowing remain subjects of intense speculation. A bony overgrowth of the nasal process of the maxilla, hypoplasia of the primary palate, and overgrowth of maxillary ossification have all been suggested as possible explanations. Although all 4 of our patients have exhibited normal facial and dental development to date, Arlis and Ward [8] speculated that congenital piriform stenosis represents a midfacial dysostosis that may be associated with endocrine and central nervous system abnormalities.

The efficacy and safety of the sublabial surgical approach are demonstrated in our patients. We believe that the transnasal approach to the piriform aperture, although effective in the adult, is limited in the confined neonatal nose and could result in significant injury to the delicate septal and lateral nasal mucosa. Although only 12 cases, including ours, have been reported, all authors have presented excellent long-term results using the sublabial approach and a short course of stenting.

Congenital piriform aperture stenosis can best be differentiated from the far more common choanal stenosis or atresia by computed tomography. We have found that direct coronal scans are the most helpful in terms of surgical planning because they are in the plane of surgical exposure (see Fig 2).

## References

- 1 Bruillette RT, Fernback SK, Hunt CE. Obstructive sleep apnea in infants and children. *J Pediatr* 1982;100:31
- 2 Guilleminault C. In: *Sleep and its disorders in children*. New York: Raven Press, 1984:217-223
- 3 Douglas B. Relief of the vestibular nasal obstruction by partial resection of nasal process of superior maxilla. *Plast Reconstr Surg* 1952;9:42
- 4 Rozner L. Nasal obstruction due to restriction of the bony nasal inlet. *Br J Plast Surg* 1964;17:287
- 5 Shetty R. Nasal pyramid surgery for correction of bony inlet stenosis. *J Laryngol Otolaryngol* 1977;91:201
- 6 Ey EH, Han BK, Towbin RB, et al. Bony inlet stenosis as a cause of nasal airway obstruction. *Radiology* 1988;168:477
- 7 Brown OE, Myer CM, Manning SC. Congenital nasal piriform aperture stenosis. *Laryngoscope* 1989;99:86
- 8 Arlis H, Ward RF. Congenital nasal pyriform aperture stenosis: isolated abnormality vs developmental field defect. *Arch Otolaryngol Head Neck Surg* 1992;118:989