

Iliac Crest Bone Graft Harvesting Techniques: A Comparison

Fernando D. Burstein, M.D., Catherine Simms, R.N., Steven R. Cohen, M.D., Fredrick Work, M.D., and Michelle Paschal, P.A.

Atlanta, Ga., and San Diego, Calif.

This study was undertaken to compare the morbidity of traditional iliac bone graft harvesting techniques for grafting alveolar clefts to minimally invasive techniques. Fifty-five age-matched patients, ages 6.5 to 16 years (mean, 11.2 years), 22 girls and 33 boys, were divided into three groups. The traditional bone window open harvesting technique served as the control group. Two different minimally invasive techniques, one that used a bone grinder and another that used a trephine, for bone harvesting were compared with the control. Both invasive techniques were statistically superior, $p < 0.05$, in terms of total time pain medication was necessary (mean of 12.0 hours for bone grinder, 17.6 hours for trephine, 26.0 hours for control), operative time for bone harvest (mean of 11 minutes for bone grinder and trephine, 20 minute for control), and mean incision length (2 cm for bone grinder and trephine, 5 cm for control). Patients exposed to the minimally invasive techniques had fewer complications, a trend toward earlier ambulation, and shorter hospital stays when compared with the bone grinder technique. The patients exposed to the bone grinder demonstrated earlier ambulation and fewer requirements for analgesia when compared with the trephine technique, although these results did not reach statistical significance. The trephine technique was useful when maxillary osteotomies were combined with alveolar bone grafting, because it provided structural bone grafts and cancellous bone. On the basis of these findings, the bone grinder is the preferred technique for harvesting alveolar bone grafts when no structural support is required. These authors no longer use the traditional bone window open harvesting technique. (*Plast. Reconstr. Surg.* 105: 34, 2000.)

There has been a great interest in the optimal donor site for obtaining alveolar bone grafts.^{1,2} Among all of the potential donor sites the calvarium and the iliac crest have received the greatest attention.^{3,4} Klein and Wolfe reported on a large series of patients who underwent harvesting of calvarial bone grafts with low morbidity.⁵ LaRossa et al. compared calvar-

ial bone to iliac bone in grafting alveolar clefts and determined that iliac bone was superior to calvarial bone.⁶ Although other donor sites continue to be advocated, the anterior iliac crest is currently the donor site of choice in most centers.⁷

Several authors have reported that iliac bone can be harvested with minimal morbidity; however, complication rates, length of hospitalization, and postoperative regimens vary widely from study to study.⁸⁻¹¹ Most reports do not attempt to measure postoperative pain or time to unassisted ambulation. Furthermore, there are significant differences between the harvesting techniques in the various reports, making intrastudy comparisons difficult. Several authors have reported minimally invasive techniques, but their series have been relatively small without objective quantification of postoperative morbidity.¹²⁻¹⁴ We were unable to locate a study in which two or more harvesting techniques were compared in terms of morbidity, time to ambulation, or pain control. In 1996, we began to look for alternatives to the traditional iliac crest bone window technique, as described by Wolfe and Kawamoto, for harvesting alveolar bone grafts that would result in shorter hospitalization and less morbidity.¹⁵ We subsequently discovered that the Fritsch bone graft-set, developed for orthopedic applications, could be adapted for iliac crest bone harvesting, and we began to use it exclusively (Howmedica Leibinger, Inc., Dallas, Texas). Later, we used a disposable bone grinder, manufactured by Sulzer Spine-Tech (Minneapolis, Minn.), which is used in spinal surgery, for iliac

From the Center for Craniofacial Disorders, Scottish Rite Children's Medical Center; the San Diego Center for Plastic, Oral, and Maxillofacial Surgery; Emory University School of Medicine; and Atlanta Plastic Surgery. Received for publication January 25, 1999; revised March 18, 1999.

crest bone harvesting. Although the nursing staff reported that the patients experienced less pain and ambulated soon after surgery, we had no measurable parameters to substantiate this impression. We undertook the current investigation to compare the morbidity of our traditional bone window technique (control) with the minimally invasive adaptation of the Fritsch bone harvest system (trephine) and the disposable Spine-Tech bone grinding harvester we are currently using.

MATERIALS AND METHODS

A total of fifty-five patients, 33 boys and 22 girls, ages 6.5 to 16 years (mean, 11.2 years), underwent alveolar bone grafting using the anterior iliac crest as a donor site. These patients were divided into three groups, matched for age and type of cleft to compare the bone harvesting techniques (Table I). For 21 patients, the control technique was used, and 21 patients underwent harvesting using the trephine technique, whereas 13 patients underwent harvesting using the disposable bone grinder. In all patients, the anterior superior iliac crest was selected for bone harvesting. After a satisfactory general anesthetic was administered, the patient was prepared and draped for sterile surgery; the area was injected with bupivacaine at both the subcutaneous and deep periosteal levels. All incisions were made approximately 2 cm medial to the iliac crest to avoid irritation of the suture line by clothing. The medial periosteum and attached musculature were incised and dissected off the bone with a Bovie hemocoagulator. The control group underwent harvesting as described by Wolfe and Kawamoto.¹⁵ The trephine and bone grinder groups necessitated a small incision, 1 to 2.5 cm, and minimal dissection to insert the bone harvesting instrument (Figs. 1 and 2). Enough bone was harvested to completely fill the alveolar cleft up to the level of

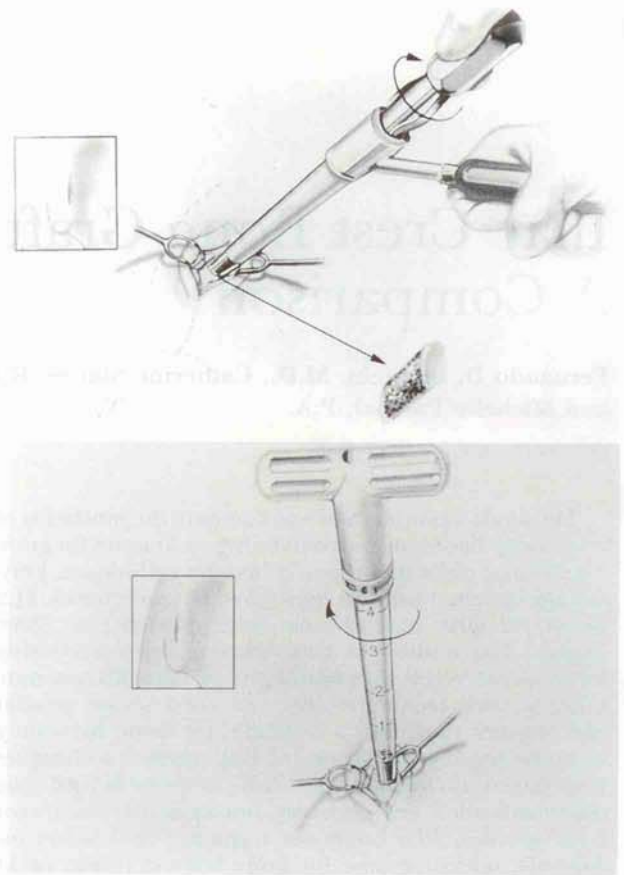


FIG. 1. (Above) Artist depiction of iliac crest bone harvesting by using the Fritsch bone harvest (trephine) system. The outer sleeve is held against inner table of iliac crest while a coring device is inserted and rotated to obtain a bone plug. (Below) Artist depiction of iliac crest bone harvesting by using the Spine-Tech grinding harvester. The grinding end of the harvester is pressed against the inner table of the iliac crest and rotated. The harvested bone fills the clear chamber.

the normal floor of the nose. The gingival incisions were closed with absorbable sutures, and the patients were placed on a soft diet for 3 weeks. In all groups, the donor-site wounds were irrigated with antibiotic solution, and a 2 × 2 cm absorbable collagen sponge impregnated with bupivacaine was placed next to the bone graft harvest site. The periosteum was reapproximated with absorbable sutures, and the skin was closed with a combination of absorbable deep subdermal sutures and subcuticular sutures followed by skin approximating tapes. No drains were used in any of the groups. All patients were admitted to the hospital and were given intravenous analgesia, and when tolerating oral medications, Tylenol with codeine as needed. All patients received intravenous cephalothin while hospitalized and a 5-day oral course when discharged. Patients were not restricted in terms of activity.

TABLE I
Patient Data

Parameter	BW	FB	BG
n	21	21	13
Male (%)	13/21 (62)	12/21 (57)	8/13 (62)
Female (%)	8/21 (38)	9/21 (43)	5/13 (38)
BCLP (%)	8/21 (38)	11/21 (52)	4/13 (31)
UCLP (%)	13/21 (62)	10/21 (48)	9/13 (69)
Mean age @ operation	11.9 yr	11.7 yr	10.1 yr

BW, bone window (control); FB, trephine; BG, bone grinder; BCLP, bilateral cleft lip and palate; UCLP, unilateral cleft lip and palate.

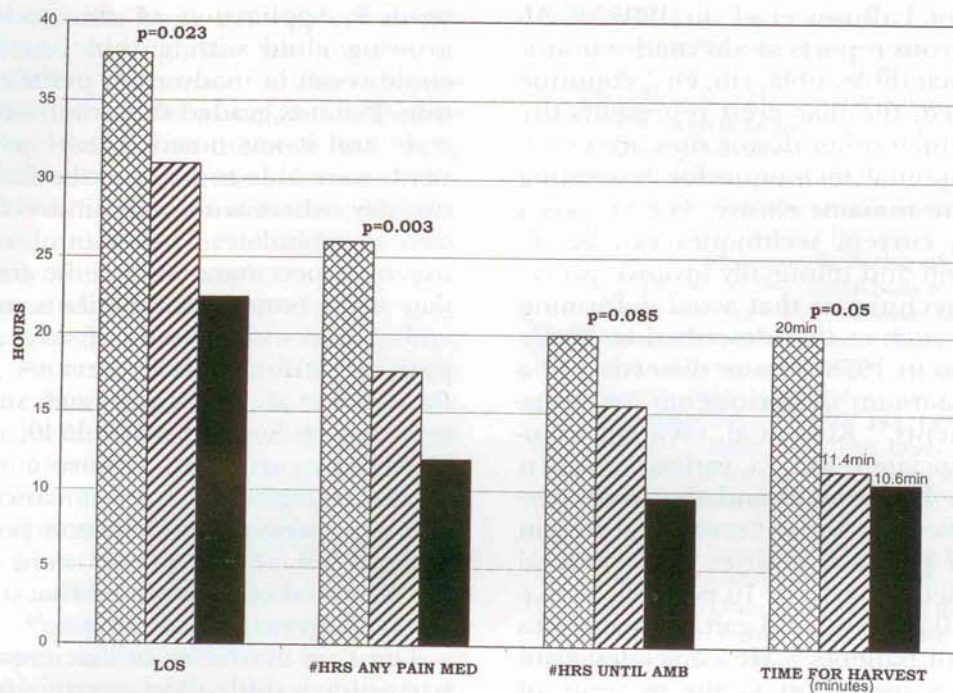


FIG. 2. Graph depicting results of study. Cross-hatched bars, bone window open harvest technique; hatched bars, trephine technique; filled bars, bone window grinder technique. Mean length of hospital stay (LOS) in hours. Time for harvest in minutes.

RESULTS

There were no infections or hematomas in the trephine or bone grinder groups. There was one infection and one hematoma in the control group. Several parameters were investigated including total amount of analgesics, total time that analgesics were taken, time to ambulation, operative harvest time, total length of stay, and length of the incisions (Fig. 2). All variables were subjected to standard statistical analysis. Comparisons were performed by using one-way analysis of variance, Kruskal-Wallis nonparametric tests, or χ^2 tests as appropriate. Most outcome measures exhibited at least some right skewing, and so comparisons across the three groups were based on Kruskal-Wallis tests and pair-wise comparisons were made by using Wilcoxon rank sum tests.¹⁶ Adjusted group comparisons were obtained by using multiple linear regression. Logarithmic transformations were performed before analysis to normalize the residual error distributions.^{17,18} We found that there were statistically significant differences in several parameters between the control group and both the trephine and bone grinder groups, because there was less time on any pain medication compared with the control group. Operative time for bone harvesting was two times faster in the

trephine and bone grinder groups when compared with the control group. The total incision length was 60 percent shorter in the trephine and bone grinder groups (mean, 2.0 cm; range, 1.0 to 3.0 cm) when compared with the control group (mean, 5 cm; range, 4 to 7.5 cm). There were no statistically significant differences in any of the parameters measured between the trephine and bone grinder groups; however, there was a trend toward faster ambulation and less analgesic requirement in the control group (Fig. 2). We found that fewer analgesics were required by the trephine and bone grinder groups and that the bone grinder group was ambulated sooner than the control and trephine groups, but these differences did not reach statistical significance (Fig. 2). Regardless of technique, patients who had iliac crest bone harvested for bilateral alveolar clefts required more analgesics than the unilateral cleft patients and hospital costs were 25 percent greater than for patients with unilateral procedures ($p = 0.004$).

DISCUSSION

The superiority of iliac crest bone over calvarial bone in alveolar bone grafting has been shown by Sadove et al. in 1990 and confirmed

by the work of LaRossa et al. in 1995.^{6,19} Although numerous reports of alternative donor sites such as mandible, tibia, rib, etc., continue to be published, the iliac crest represents the standard by which other donor sites are evaluated.¹² The optimal technique for harvesting iliac crest bone remains elusive. For purposes of discussion, current techniques can be divided into open and minimally invasive procedures. Open techniques that avoid deforming the iliac crest such as that described by Wolfe and Kawamoto in 1978 require dissection of a considerable amount of periosteum and muscular attachments.¹⁵ Kurz et al. reviewed complications associated with a variety of open techniques in 1989 and found that pain persisting for more than 3 months was reported in 15 percent of patients, injuries to the lateral femoral cutaneous nerve in 10 percent, hematoma in 4 to 10 percent, and gait abnormalities in 3 percent of patients.²⁰ He correlated pain and hematoma formation to the quantity of medial or lateral dissection of the attached periosteum. Canady et al. in 1993 reviewed by means of a questionnaire 50 consecutive patients undergoing iliac crest bone harvest.²¹ They reported 7 percent of patients with some numbness of the hip and leg and 39 percent with limping for 1 to 4 weeks, whereas 22 percent of patients classified their pain as severe with an average hospitalization of 2 to 3 days. Others have reported rare complications with open techniques including arterial injury, peritoneal perforation, hernias, and stress fractures of the ilium.²²⁻²⁵ In 1996, Dawson et al. investigated the pain associated with harvesting of a corticocancellous iliac crest block and concluded that, with patient-controlled analgesia, the pain was "not severe."²⁶ Other authors have reported a variety of less invasive harvesting techniques. In 1985, Caddy and Reid reported a percutaneous lateral trephine harvesting technique through multiple stab incisions but did not report on their morbidity.²⁷ Minimally invasive techniques include the use of cylindrical osteotomes as reported by Shepard and Dierberg in 1987 and a mechanized coring technique reported by Billmire and Rotatori in 1994.^{13,14,27-29} Despite what is described as adequate bone harvest with minimal complications, these coring techniques have not been widely accepted. In 1993, McGurk et al. reported on an anterior transcristal approach with a trephining instrument passed deeply between the cortical plates in 11 adult pa-

tients.²⁹ Application of this technique in a growing child with a thin cancellous space could result in inadvertent peritoneal penetration. Patients graded their morbidity on a pain scale and it was noted that 81 percent of patients were able to walk on the first postoperative day, whereas the remainder took up to 4 days to ambulate. Thaller et al. reported the use of a percutaneous needle for harvesting iliac crest bone in 24 patients and reported ambulation within hours of surgery in an outpatient setting without serious morbidity.³⁰ Boustred et al., in an approach similar to that reported by Scott et al. in 1949, used a small Volkmann curette to remove a core of iliac crest cartilage and harvest cancellous bone with the patient in the prone position in 14 patients.^{13,31} They reported mild notching of the crest and acknowledged that the long-term effect on growth is not known.¹³

The true morbidity of iliac crest bone graft harvesting is difficult to ascertain from the current literature, because many different techniques for harvesting are used and morbidity is often not reported or inadequately measured. Likewise, comparison of the morbidity of iliac crest bone graft harvesting to other donor sites may be affected by the harvest techniques. The present study is unique in that three harvesting techniques were performed in matched patient groups by the same surgeons while minimizing variability in closure, local anesthetics, and postoperative regimen. This allowed us to compare the effect of the actual harvesting techniques in an objective and standardized manner.

There were statistically significant differences in the time necessary for bone harvest, the length of the skin incision necessary for bone harvest, and the total time that narcotic analgesics were necessary between the control group and both the trephine and bone grinder groups (Fig. 2). There was a statistically significant increase in the amount of analgesics and costs of hospitalization in those patients with bilateral alveolar clefts, regardless of harvesting technique. Although hospitalization time and time to ambulation were decreased in both the trephine and bone grinder groups when compared with the control group, the differences did not reach statistical significance (Fig. 2). This is probably due to the relatively small sample size in our study. Interestingly, there was a definite trend toward decreased use of analgesics, a shorter hospital stay, and faster

ambulation with the bone grinder versus the trephine group, although this was not a statistically significant difference. Other authors have correlated the pain associated with iliac crest bone harvesting with the amount of subperiosteal dissection, which detaches muscular insertions.²⁰ Our findings corroborate their reports, because much less periosteal dissection was necessary with the trephine and bone grinder groups when compared with the control group. A larger amount of soft-tissue dissection was also necessary in the bilateral clefts because more bone was required, resulting in an increase in analgesic requirements. With the bone grinder technique, the muscular attachments on only the medial crest are disturbed, whereas with the trephine technique the outer cortex muscular attachments are torn as the core is pulled medially by the trephine. When compared with historical reports of various open techniques and to our own open control group, both the trephine and bone grinder harvest techniques had significantly fewer complications.¹⁹⁻²⁶

All three techniques provided adequate bone for even the widest clefts. The trephine technique provides a corticocancellous core that can be decorticated to obtain pure cancellous bone. Alternatively, this core can be used as a strut graft for stabilization of maxillary osteotomies or in bilateral clefts after premaxillary repositioning. The bone grinder technique produces a mixed cortical cancellous paste that can be easily packed into the most irregular cleft with no hard particles that might later extrude. The effect of the small amount of cortical bone included in the bone grinder harvested bone on graft take is not known at this time. Both the trephine and bone grinder techniques offer significantly lower rates of morbidity than conventional control techniques while providing adequate bone for alveolar bone grafting.

Fernando D. Burstein, M.D.
The Center for Craniofacial Disorders
5455 Meridian Mark Rd., Suite 200
Atlanta, Ga. 30342
fburstein@aol.com

REFERENCES

- Laurie, S. W., Kaban, L. B., Mulliken, J. B., and Murray, J. E. Donor-site morbidity after harvesting rib and iliac bone. *Plast. Reconstr. Surg.* 73: 933, 1984.
- Sindet-Pedersen, S., and Enemark, H. Mandibular bone grafts for reconstruction of alveolar clefts. *J. Oral Maxillofac. Surg.* 46: 533, 1988.
- Wolfe, S. A., and Berkowitz, S. The use of cranial bone grafts in the closure of alveolar and anterior palatal clefts. *Plast. Reconstr. Surg.* 72: 659, 1983.
- Witsenburg, B. The reconstruction of anterior residual bone defects in patients with cleft lip, alveolus and palate. *J. Maxillofac. Surg.* 13: 197, 1985.
- Kline, R. M., Jr., and Wolfe, S. A. Complications associated with the harvesting of cranial bone grafts. *Plast. Reconstr. Surg.* 95: 5, 1995.
- LaRossa, D., Buchman, S., Rothkopf, D., et al. A comparison of iliac and cranial bone in secondary grafting of alveolar clefts. *Plast. Reconstr. Surg.* 96: 789, 1995.
- Freihofer, H. P., Borstlap, W. A., Kuijpers-Jagtman, A. M., et al. Timing and transplant material for closure of alveolar clefts: A clinical comparison of 296 cases. *J. Craniomaxillofac. Surg.* 21: 143, 1993.
- Beirne, J. C., Barry, F. A., and Brady, V. B. Donor site morbidity of the anterior iliac crest following cancellous bone harvest. *Int. J. Oral Maxillofac. Surg.* 25: 268, 1996.
- Mrazik, J., Amato, C., Leban, S., and Mashberg, A. The ilium as a source of autogenous bone for grafting: Clinical considerations. *J. Oral Surg.* 38: 29, 1980.
- Wilson, P. A. Pain relief following iliac crest bone harvesting. *Br. J. Oral Maxillofac. Surg.* 33: 242, 1995.
- Rudman, R. A. Prospective evaluation of morbidity associated with iliac crest harvest for alveolar cleft grafting. *J. Oral Maxillofac. Surg.* 55: 219, 1997.
- Bergland, O., Semb, G., Abyholm, F. E., et al. Secondary bone grafting and orthodontic treatment in patients with bilateral complete clefts of the lip and palate. *Ann. Plast. Surg.* 17: 460, 1986.
- Boustred, A. M., Fernandes, D., and van Zyl, A. E. Minimally invasive iliac cancellous bone graft harvesting. *Plast. Reconstr. Surg.* 99: 1760, 1997.
- Billmire, D. A., and Rotatori, S. Use of the CORB needle biopsy for the harvesting of iliac crest bone graft. *Plast. Reconstr. Surg.* 93: 416, 1994.
- Wolfe, S. A., and Kawamoto, H. K. Taking the iliac bone graft: A new technique. *J. Bone Joint Surg. Am.* 60: 411, 1978.
- Lehmann, E. L. *Nonparametrics: Statistical Methods Based on Ranks.* San Francisco: Holden-Day, 1975.
- Box, G. E., and Cox, D. R. An analysis of transformations. *J. R. Stat. Soc. B.* 26: 211, 1964.
- Keene, O. N. The log transformation is special. *Stat. Med.* 14: 811, 1995.
- Sadove, A. M., Nelson, C. L., Eppley, B. L., et al. An evaluation of calvarial and iliac donor sites in alveolar cleft drafting. *Cleft Palate J.* 27: 225, 1990.
- Kurz, L. T., Garfin, S. R., and Booth, R. E. Harvesting autogenous iliac bone grafts: A review of complications and techniques. *Spine* 14: 1324, 1989.
- Canady, J. W., Zeitler, D. P., Thompson, S. A., et al. Suitability of the iliac crest as a site for harvest of autogenous bone grafts. *Cleft Palate Craniofac. J.* 30: 579, 1993.
- Escalas, F., and Wald, R. L. Combined traumatic arteriovenous fistula and ureteral injury: A complication of iliac bone-grafting. *J. Bone Joint Surg. Am.* 59: 270, 1977.
- Bosworth, D. M. Repair of herniae through iliac crest defects. *J. Bone Joint Surg. Am.* 37: 1069, 1955.
- Mrazik, J., Amato, C., Leban, S., et al. The ilium as a source of autogenous bone for bone grafting: Clinical considerations. *J. Oral Surg.* 38: 29, 1980.
- Massey, E. W. Meralgia paresthetica secondary to trauma of bone graft. *J. Trauma* 20: 342, 1980.

26. Dawson, K. H., Egbert, M. A., and Myall, R. W. Pain following iliac crest bone grafting in alveolar clefts. *J. Craniomaxillofac. Surg.* 24: 151, 1996.
27. Caddy, C. M., and Reid, C. D. An atraumatic technique for harvesting cancellous bone for secondary alveolar bone grafting in cleft palate. *Br. J. Plast. Surg.* 38: 540, 1985.
28. Shepard, G. H., and Dierberg, W. J. Use of the cylinder osteotome for cancellous bone grafting. *Plast. Reconstr. Surg.* 80: 129, 1987.
29. McGurk, M., Barker, G., and Grime, P. The trephining of bone from the iliac crest: An anterior approach. *Int. J. Oral Maxillofac. Surg.* 22: 87, 1993.
30. Thaller, S. R., Patel, M., Zimmerman, T., and Feldman, M. Percutaneous iliac bone grafting of secondary alveolar clefts. *J. Craniofac. Surg.* 2: 135, 1991.
31. Scott, W., Petersen, R. C., and Grant, S. A method of procuring iliac bone by trephine curettage. *J. Bone Joint Surg. Am.* 31: 860, 1949.