

Aesthetic and Reconstructive Rhinoplasty

A Personal Perspective

by *Fernando D. Burstein, M.D., FACS, FAAP*

The nose defines the aesthetics of the face and is often the first facial characteristic that the eye catches. Its central location, protrusion from the facial plane and relationship to overall facial proportions makes it a major aesthetic landmark. In addition to its aesthetic role it has several important functions. These include air humidification, filtration and warming. Olfaction is dependent on air reaching the olfactory filaments which are located in the upper nasal vault. The paranasal sinuses drain into the nasal passages, and can be secondarily affected by alterations in nasal anatomy. The external nose is composed of paired nasal bones, upper and lower lateral cartilages which meet at the central septum. The nasal bones are attached to the maxilla creating the piriform aperture, the bony nasal inlet. The septum occupies the central pillar of the nasal pyramid, playing an important role in the support of external nasal structures as well as internal nasal physiology. The paired turbinates line the lateral internal nasal walls and help to regulate airflow, humidify

and filter the air. The nasal mucosa is lined with fine hairs which are important in filtration and mucous producing cells which lubricate the nasal passages and help to carry away the filtered materials.

Rhinoplasty, surgery of the external nose, can be divided into aesthetic and reconstructive procedures which often overlap. Reconstructive rhinoplasty may be required because of trauma, previous surgery, or congenital deformity. There is often a combination of aesthetic and functional goals that need to be considered and discussed between the surgeon and patient. In the initial patient encounter I document significant nasal history such as trauma, previous surgery and perform a detailed external and internal nasal examination. Nasal allergies, smoking history, use of topical or systemic medications, as well as overall physical health are documented. The patients are asked to do their own aesthetic analysis by dividing the nose into thirds and describing it on frontal and lateral view. This leads into a discussion of their goals and expectations followed by photographs. I recommend that my patients who want external nasal changes undergo computerized facial imaging prior to surgery. This allows the patient and surgeon to view the potential surgical results. These computerized images provide a guide or template which I refer to during surgery. The surgery is performed on an outpatient basis under general anesthesia. The procedure takes between one and two hours, depending on the amount of internal nasal surgery that is combined with the aesthetic procedure. Any functional component may be covered by health insurance while the aesthetic component is generally not eligible for coverage. Costs for aesthetic nasal surgery range from \$1500-\$5000, not including operating room and anesthesia charges.

The most common aesthetic nasal procedure is reductive rhinoplasty. The following is a brief synopsis

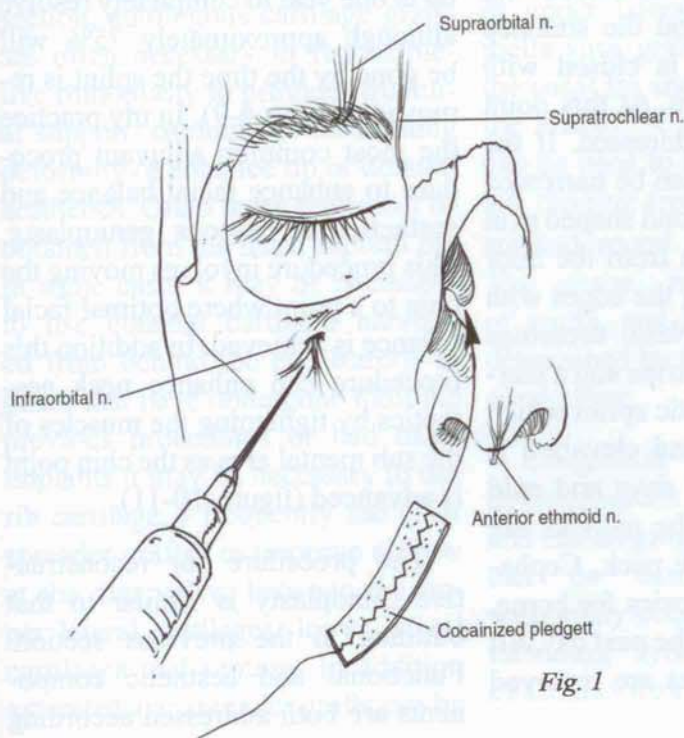


Fig. 1

of the surgical procedure and after-care. After a general anesthetic is administered long acting Mepivacaine injections are used to give regional blocks which will markedly decrease postoperative discomfort, figure 1. The internal nasal mucosa is painted with 4% cocaine to decrease vascular flow. I prefer an external rhinoplasty approach using a transverse columella incision because of the full visualization it provides. This allows for precision sculpting, grafting with more predictable results, and the columella incision heals very well. The nasal skin is thus lifted exposing the entire external anatomy.

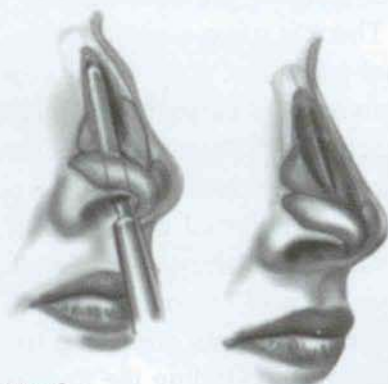

Fig. 2

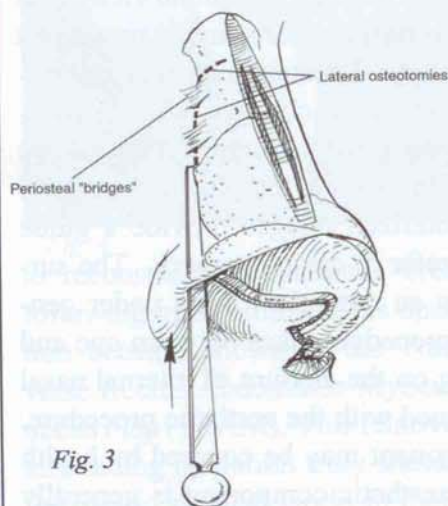


Fig. 3

If there is a functional component it is addressed at this time. The septum can be easily accessed by elevating mucoperichondrial flaps and any deviated portions are removed, while preserving dorsal and caudal

supporting struts. If the inferior turbinates are enlarged, causing airway obstruction, they are trimmed and cauterized. The septal flaps are sutured to each other, eliminating the need for nasal packing. The height of the dorsum is then addressed using rasps to remove the bony hump and a #11 scalpel to shave the cartilaginous component (figure 2). This will result in a flattened or "open dorsum" so lateral nasal osteotomies are necessary (figure 3). These are performed through an entirely intranasal approach using a tiny 2mm osteotome which is very precise and results in stable osteotomies. Bringing the nasal bones medially closes the open roof and decreases the width of the bridge.

Finally, the nasal tip is addressed. If it is too bulky the lower lateral cartilages, which define the tip, can be trimmed shortened or weakened as necessary to achieve the desired effect (figure 4). A variety of cartilage grafts can be sculpted from the septal cartilage and used to enhance tip support or definition (figure 5). All internal incisions are closed with resorbable suture and the stairstep columella incision is closed with nonresorbable suture. At this point the nasal base is addressed. If the base is too wide it can be narrowed by removing a diamond shaped skin and mucosal pattern from the floor of nose and suturing the edges with resorbable suture. Nasal dressings consist of adhesive strips and a thermally activated plastic splint which is custom fitted. Head elevation is recommended for 5 days and cold packs for 24 hrs. The patients are given a Medrol dose pack, Cephallexin and oral analgesics for home. Showering can start the next day. All nonresorbable sutures are removed

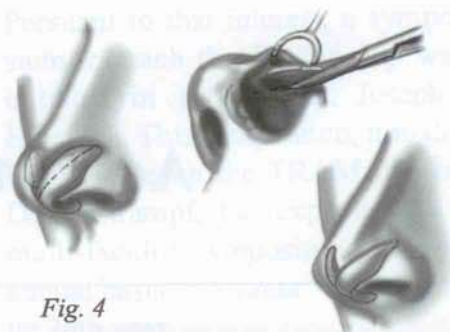


Fig. 4

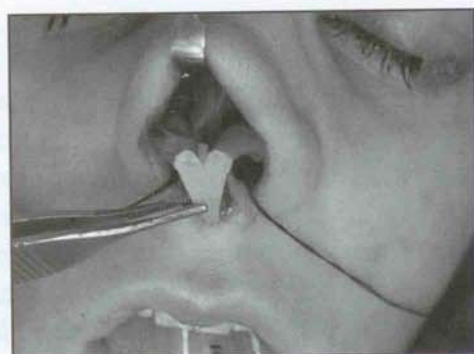


Fig. 5

in 5-7 days and the nasal splint is removed at the same time. Patients are given nasal saline drops and a topical decongestant to help clear the nasal passages. Exercise can be resumed after the splint is off but no heavy contact is recommended for six weeks. The patients are told that nasal congestion may persist for up to six weeks. Nasal edema can take up to one year to completely resolve although approximately 75% will be gone by the time the splint is removed (figures 6-9). In my practice the most common adjuvant procedure to enhance facial balance and aesthetics is osseous genioplasty. This procedure involves moving the chin to a point where optimal facial balance is achieved. In addition this procedure can enhance neck aesthetics by tightening the muscles of the sub mental area as the chin point is advanced (figures 10-11).

The procedure for reconstructive rhinoplasty is similar to that outlined in the previous section. Functional and aesthetic components are both addressed according

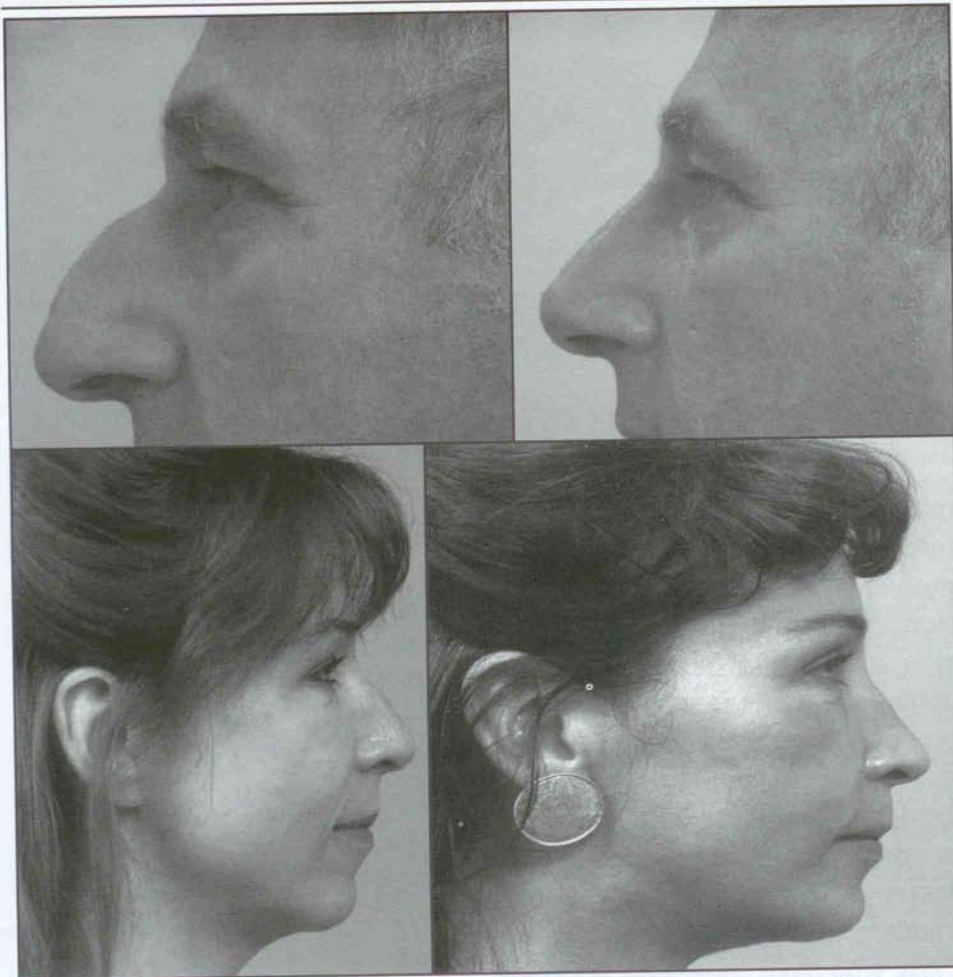


Fig. 6-7 (upper), Fig 8-9 (lower)

to the preoperative plan based on history, examination and computerized imaging. In addition to the maneuvers outlined in the preceding section, autologous cartilage grafts are often necessary in reconstructive rhinoplasty to provide structural support, camouflage an existing deformity or enhance tip or dorsum aesthetics. Often these grafts can be obtained from the nasal septum but in some cases it may be necessary to use conchal cartilage harvested from behind the ear. Rarely, in noses that have undergone multiple previous procedures or had nasal implants it may be necessary to use rib cartilage. I frequently use "alar spreader grafts" to improve airflow at the alar valve, between the upper lateral cartilages, lower lateral cartilages and septum. In addition extended alar spreader grafts can be

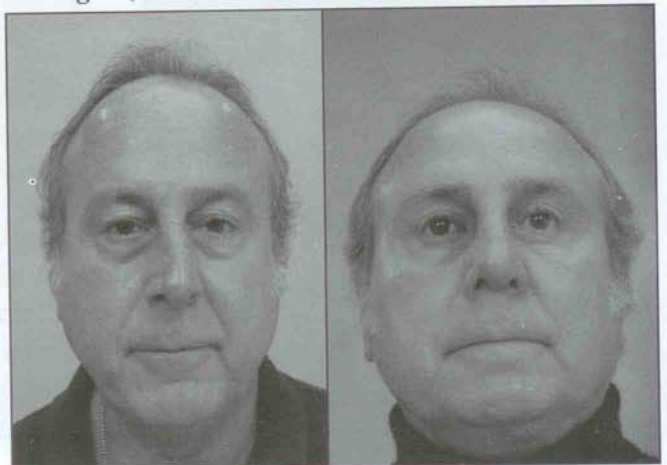used to enhance the profile or disguise a concavity (figures 12-14). Batten grafts are used to strengthen the lateral nasal sidewall as well as camouflage defects in the lower or upper lateral cartilages. Collumella strut grafts are used to raise the nasal tip and provide support to the airway. A variety of tip grafts can be used to enhance tip aesthetics, ranging from "shield grafts" to stacked round grafts. The shape, number of grafts, and size is determined by the desired effect.

Congenital nasal deformities are varied and challenging. They can be associated with many conditions including syndromic craniosynostosis,

dwarfism, and most frequently cleft lip and palate. Unlike rhinoplasty in adults congenital deformities require a sequential approach since structural anatomic changes will accompany facial growth. Cleft deformities serve as an example of my approach to congenital deformities and include unilateral and bilateral conditions. An external approach is preferred at 4-6 years of age followed by an intermediate stage, if necessary at 9-12 yrs of age and the final repair in adolescence. The unilateral deformity is characterized by asymmetry which includes the shape of the lower lateral cartilages, nostril and septal deviation (figure 15). The initial repair involves mobilization of the affected cartilage with suspension to the non affected side with resorbable sutures. The nostril base is repositioned with a Y to V advancement. This can be repeated if the deformity recurs with growth. The final repair in adolescence is similar to that outlined in the preceding reconstructive sections and includes both functional and aesthetic considerations (figures 16-17).

The bilateral deformity is approached at similar time intervals. It is characterized by a shortened columella, and broad nasal tip. The tip can be initially addressed by length-

Fig. 10, 11



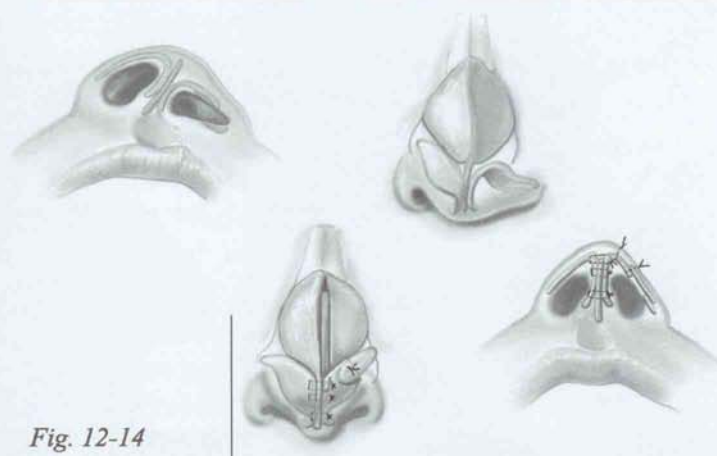


Fig. 12-14

ening the collumella with small skin flaps taken from the lip repair scars and advancing the footplates of the lower lateral cartilages with resorbable sutures. The base of the nose is addressed with bilateral Y to V advancements. In adolescence a variety of cartilage grafts can be utilized to lengthen the nasal tip in addition to the standard reconstructive maneuvers. In individuals with cleft lip and palate the nose is often addressed in conjunction with lip reconstruction or other adjuvant procedures (figures 15-19).

As with any surgical procedures a thorough discussion of risks and benefits is essential. In rhinoplasty

risks include visible scars, and unforeseen aesthetic or functional problems which may require revision. A thorough and honest discussion of realistic expectations and potential pitfalls is essential in the preoperative period. In general revision surgery should be postponed until final healing at 9-12 months. In my practice revision surgery is necessary in less than 5% of patients. Patients who are at higher risk are those who have undergone previous nasal procedures where old scar tissue, loss of skin elasticity and lack of autologous cartilage for grafting present additional challenges. ■



Fernando D. Burstein, M.D.

Dr. Fernando Burstein has been a member of Atlanta Plastic Surgery since 1989. He completed his training in otolaryngology, head, and neck surgery at UCLA, followed by a Plastics and Reconstructive Surgery residency at Yale University and a Craniofacial Fellowship at UCLA. He is board certified in both Otolaryngology and Plastic and Reconstructive Surgery. Dr. Burstein has served as the Medical Director at the Center for Craniofacial Disorders at Children's Healthcare of Atlanta since 1989. He is an Associate Clinical Professor at Emory University, Department of Plastic and Reconstructive Surgery. He specializes in aesthetic and reconstructive surgery of the face and neck. He is the author of over 100 articles and book chapters and has given numerous national and international presentations. His personal interests include cycling, skiing, and hiking.

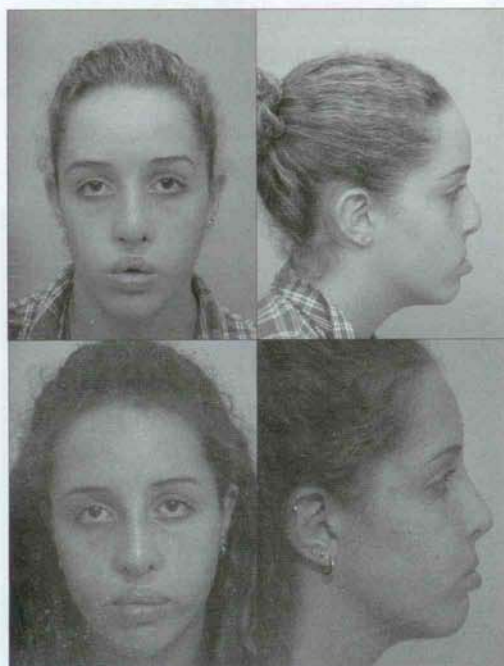

Fig. 15-19

